# 第73回 BTC
# 画像抄録

# 症例 1

九州労災病院
病理診断科

症例1

# 単純CT

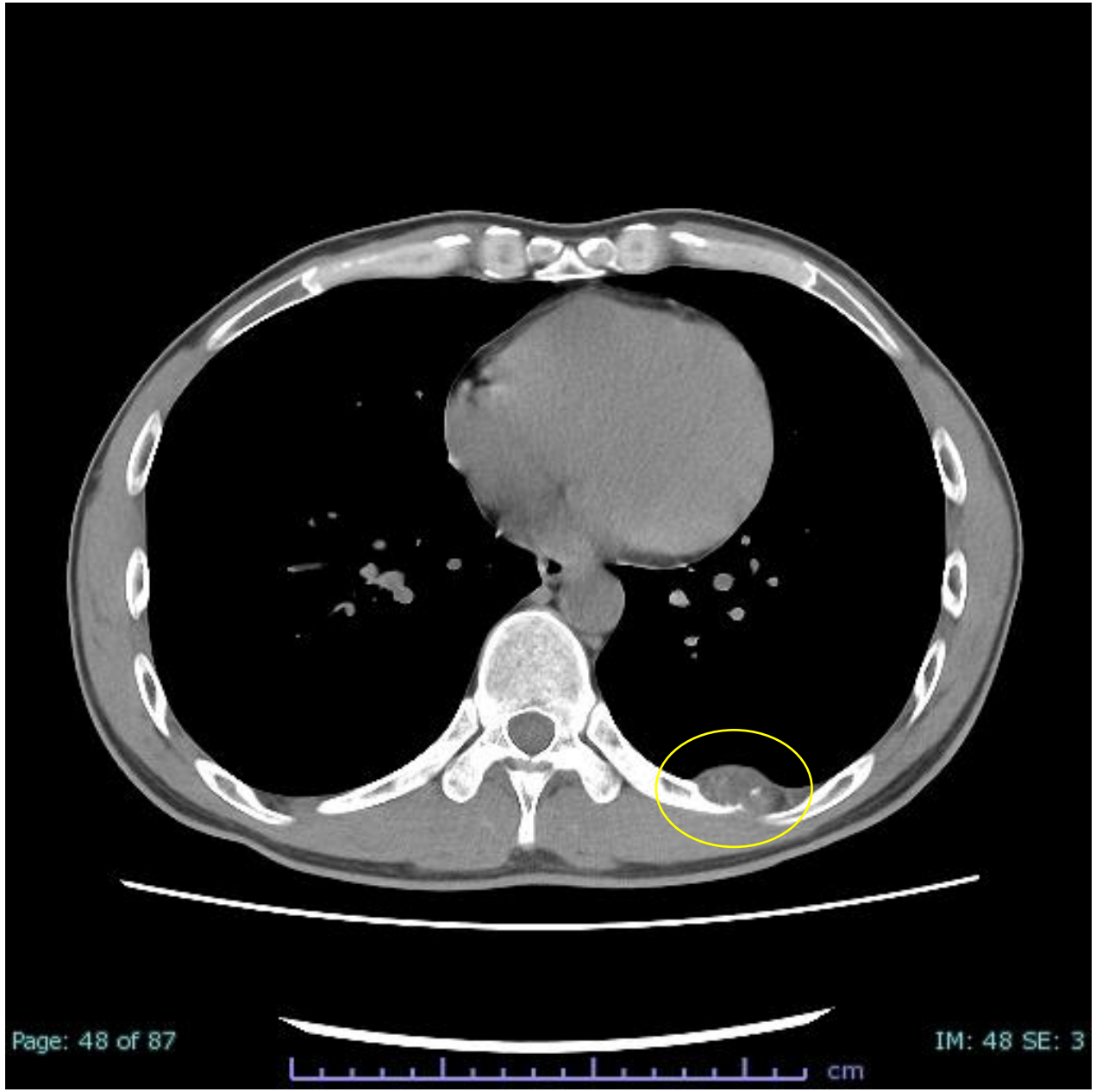


# 造影CT

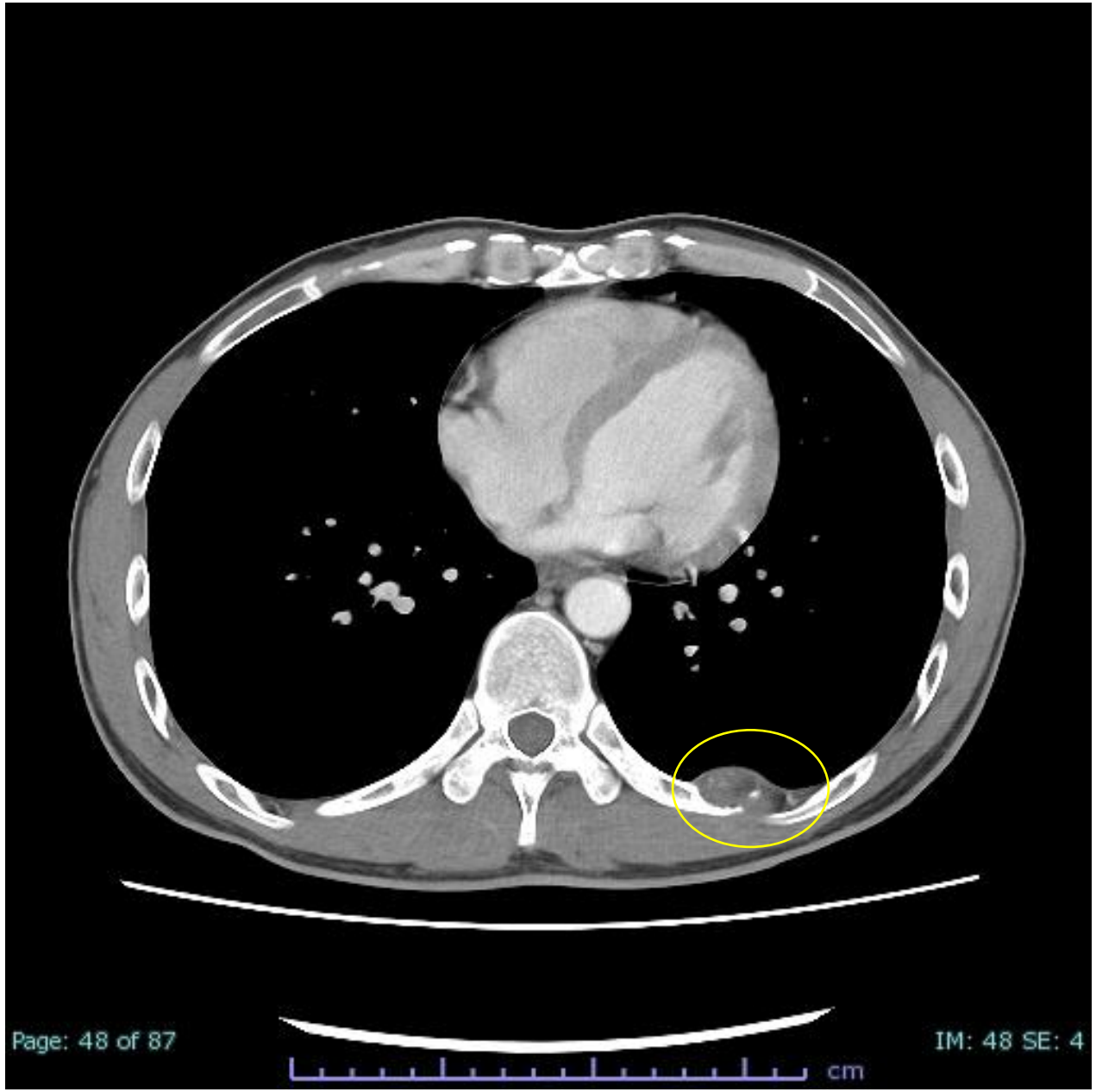

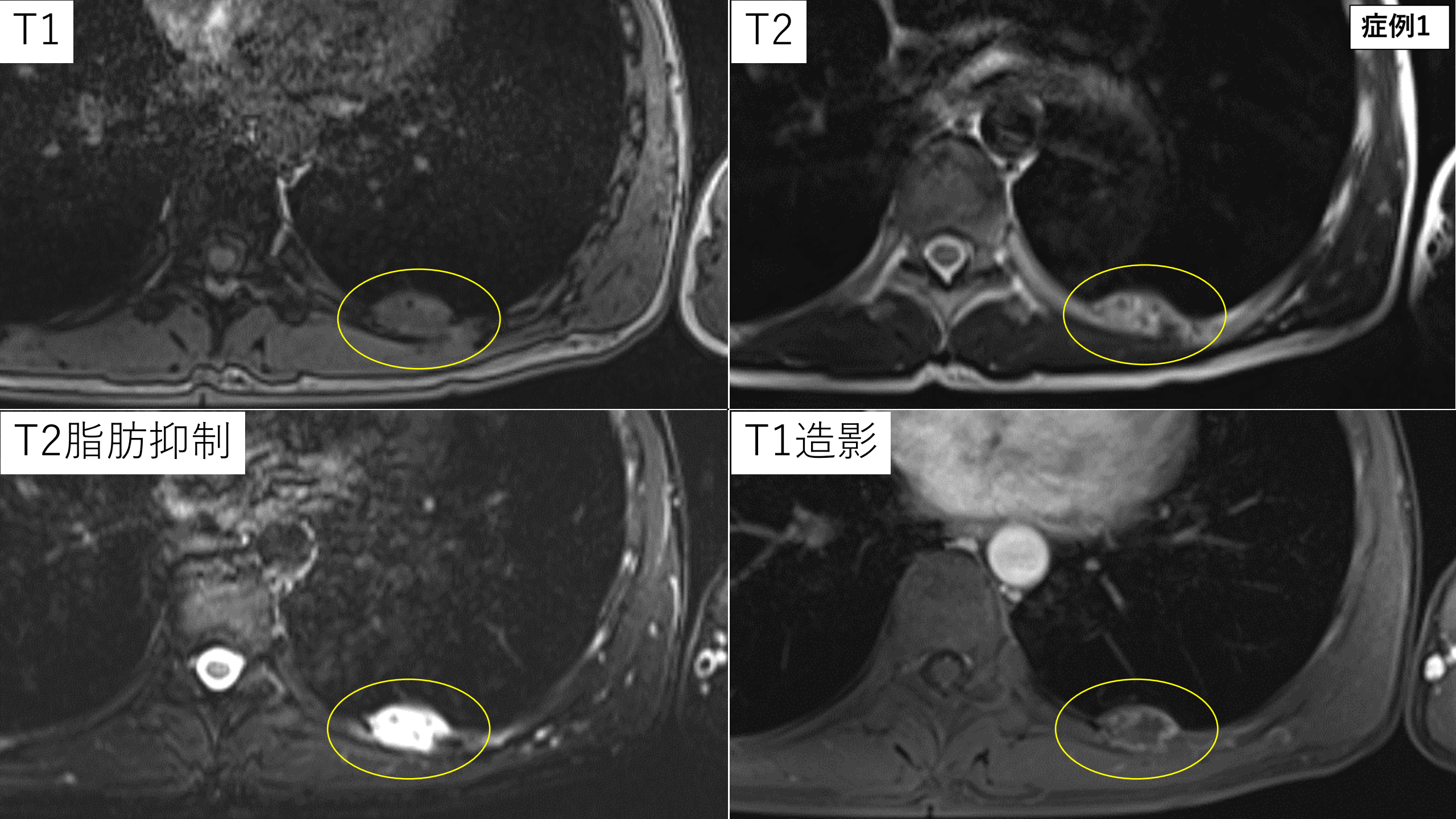
T1
T2
症例1
T2脂肪抑制
T1造影

PET-CT

症例1

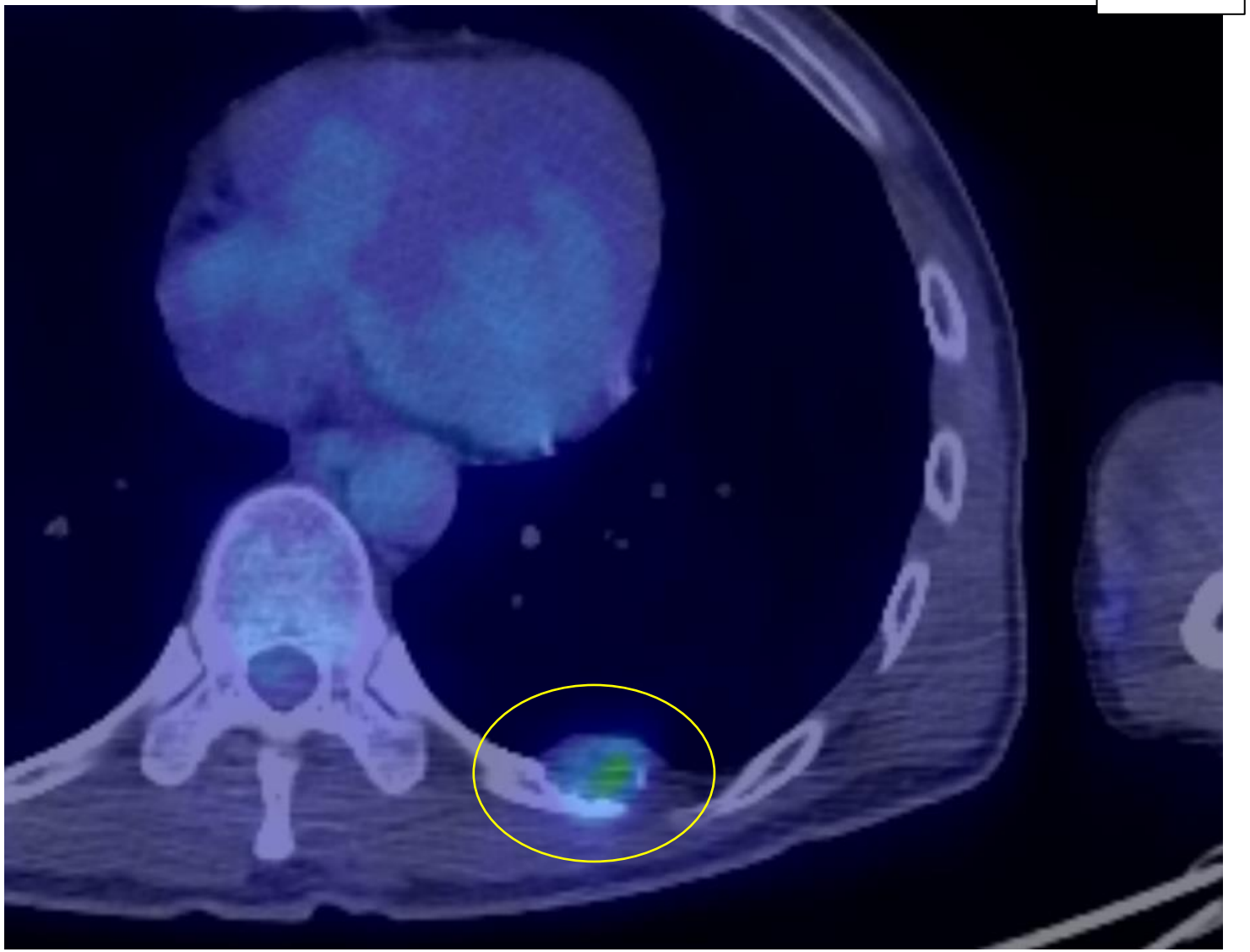

SUV max: 2.36

症例1

# 摘出検体

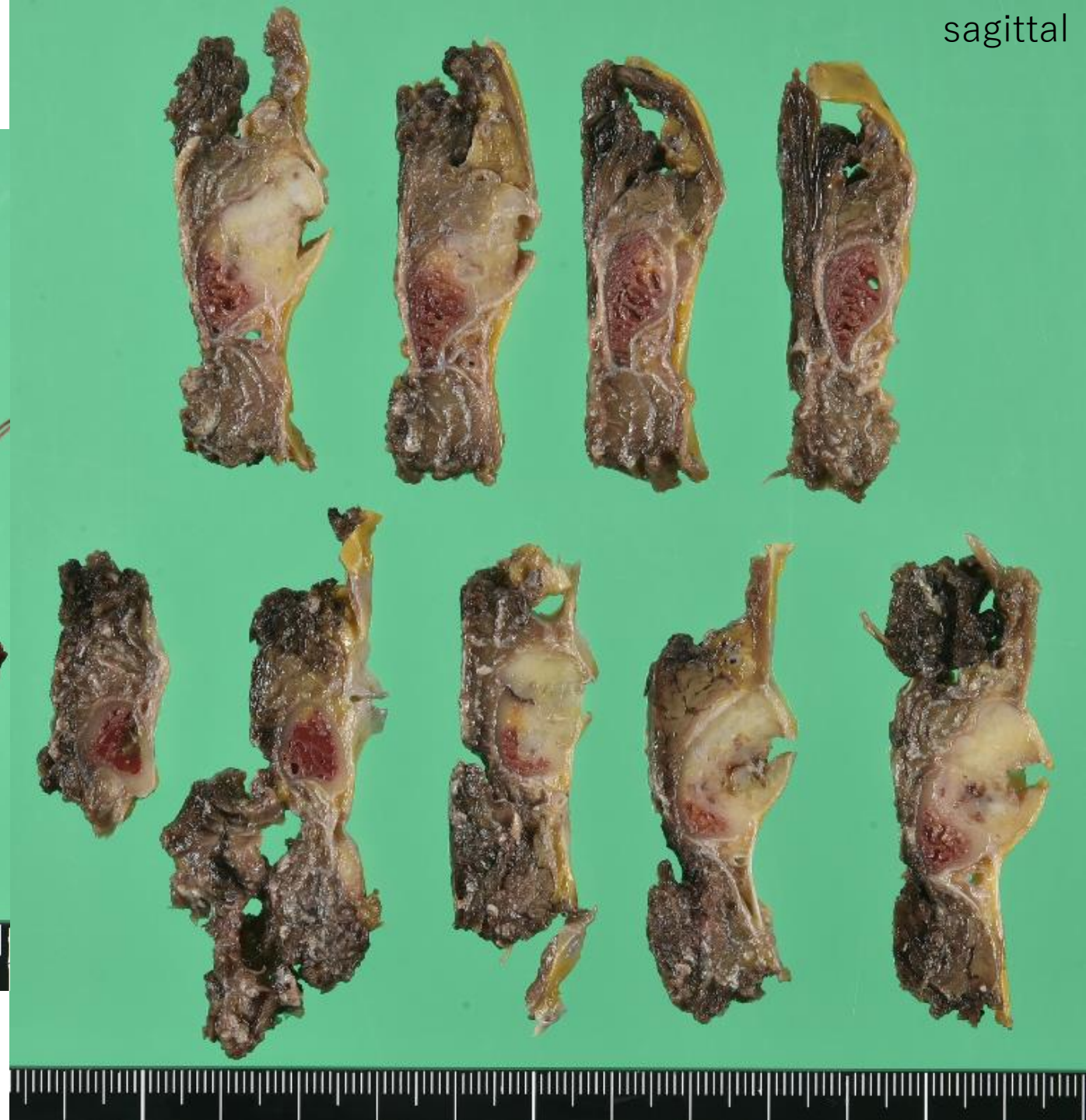

# 症例 2

岡山大学 大学院医歯薬学総合研究科
病理部(腫瘍病理)

症例2
T1WI
T2WI
脂肪抑制T2WI

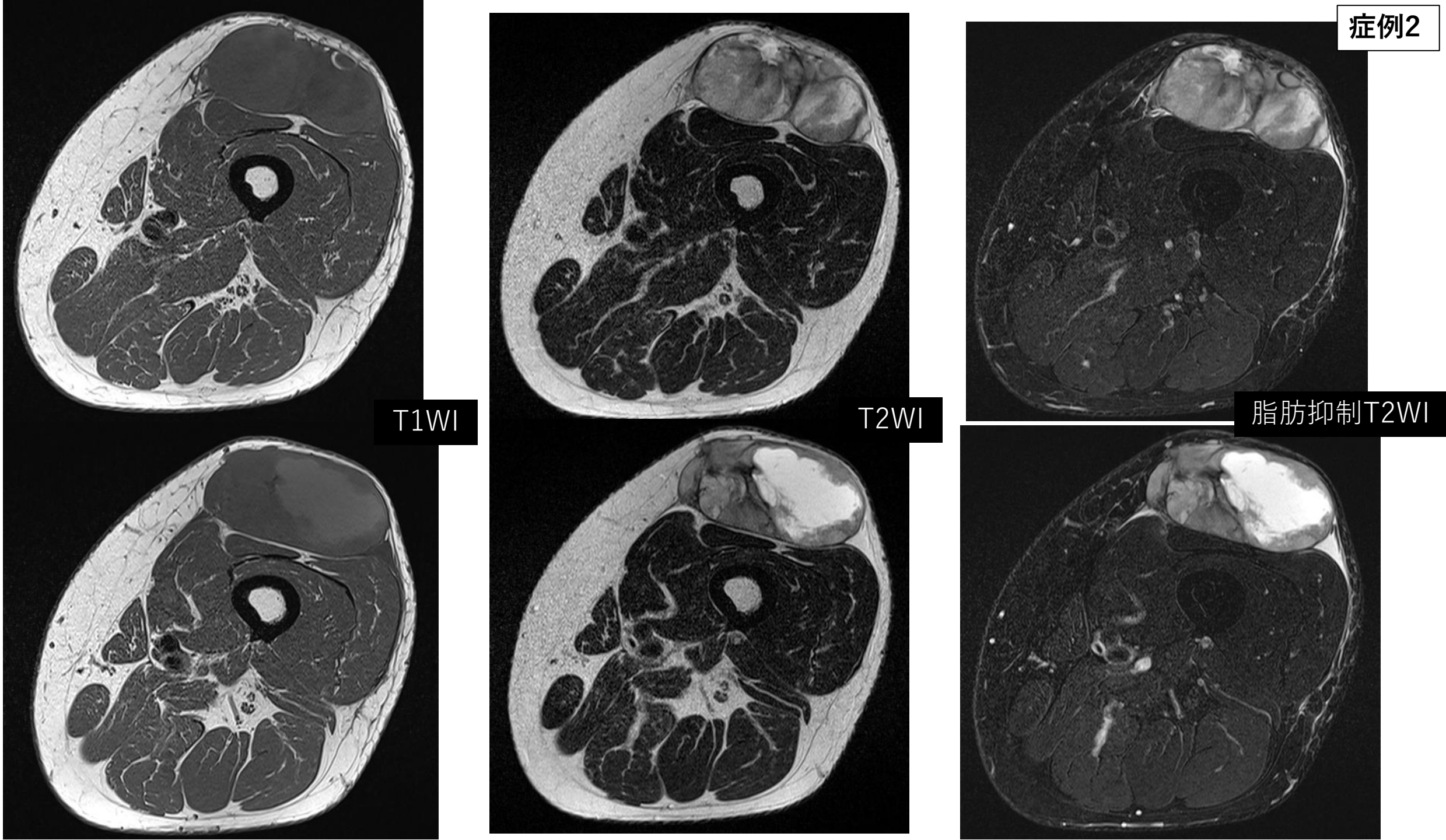
症例2
T1WI
T2WI
脂肪抑制T2WI

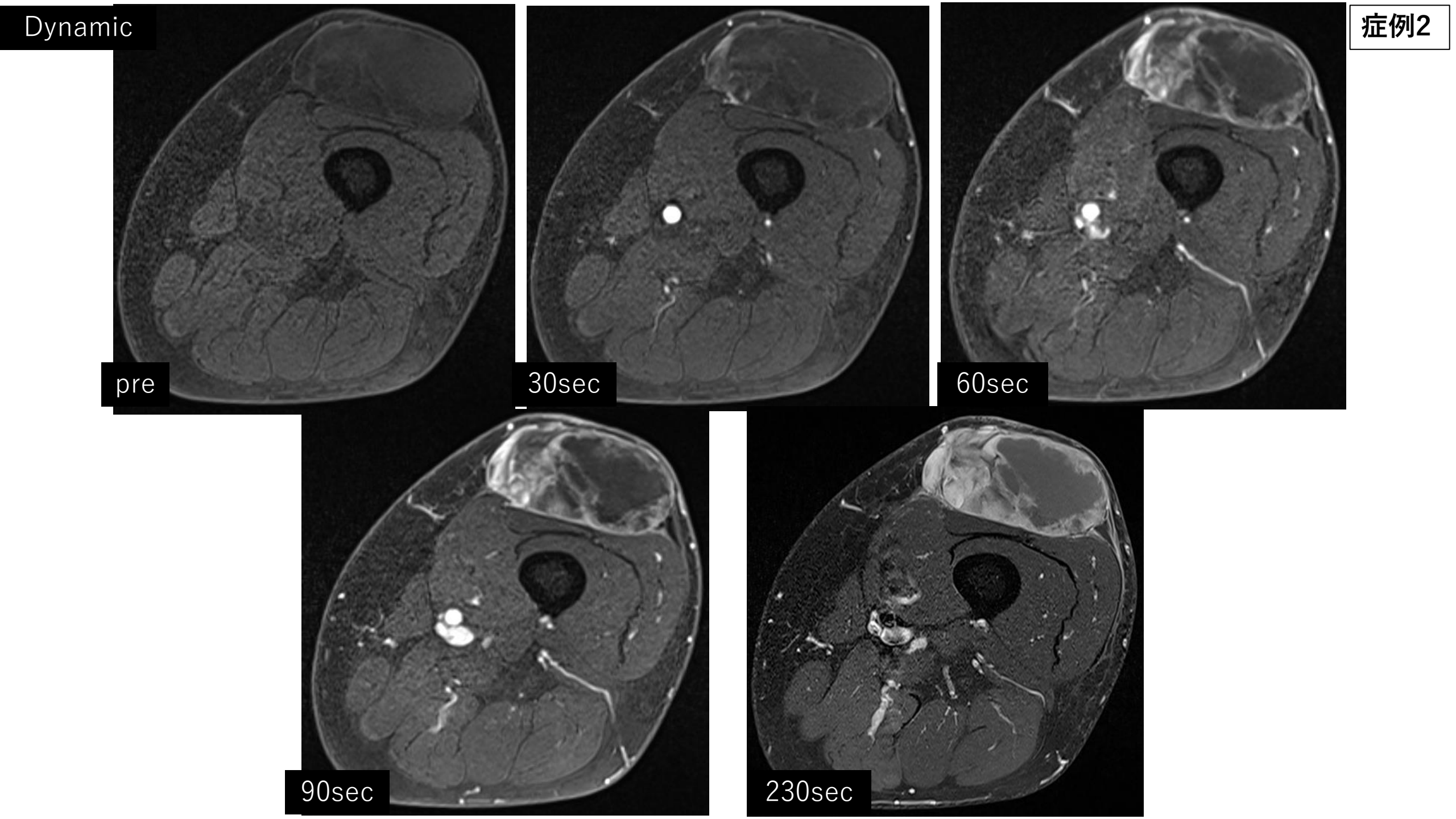
Dynamic
症例2
pre
30sec
60sec
90sec
230sec

# 配布標本① 針生検検体

症例2

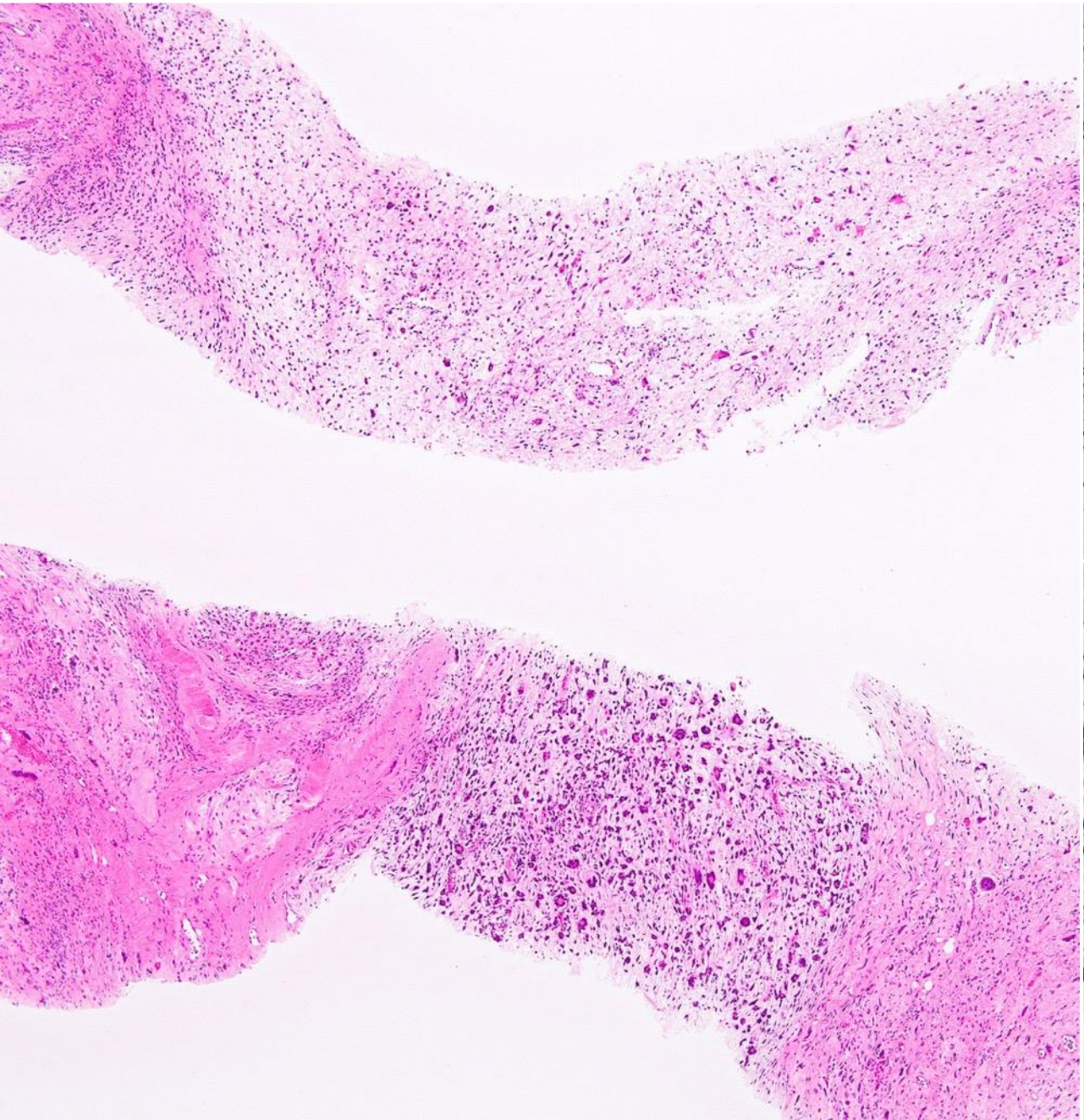

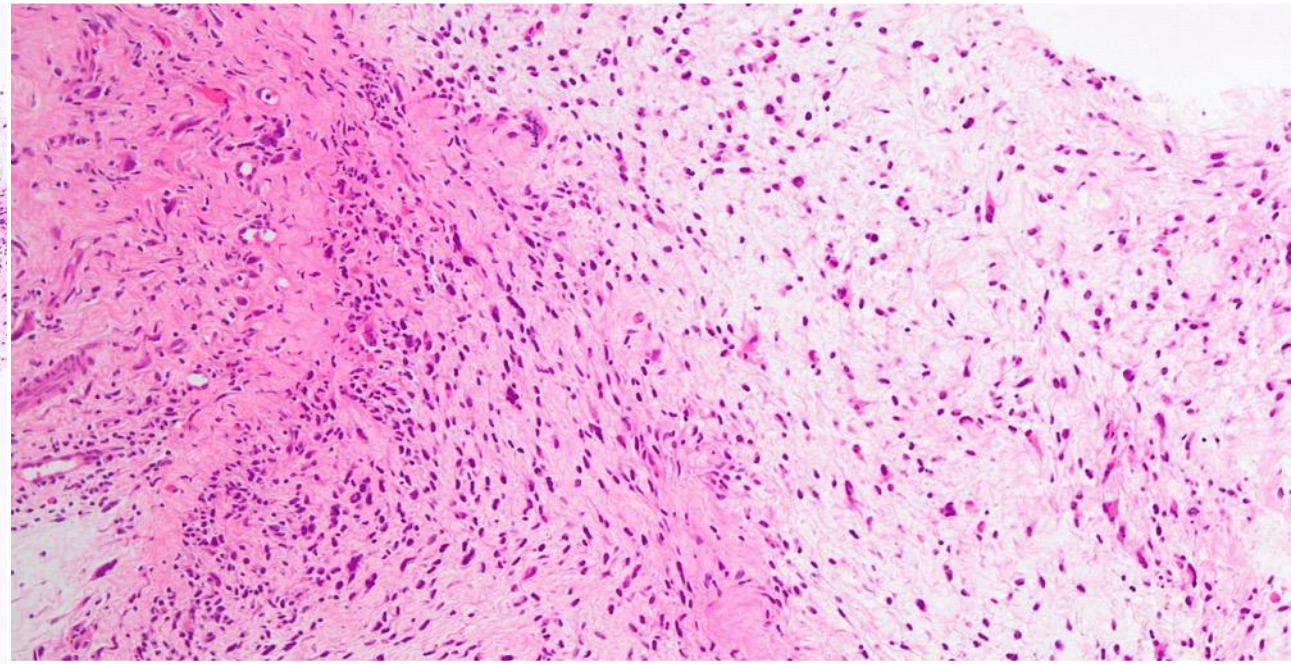

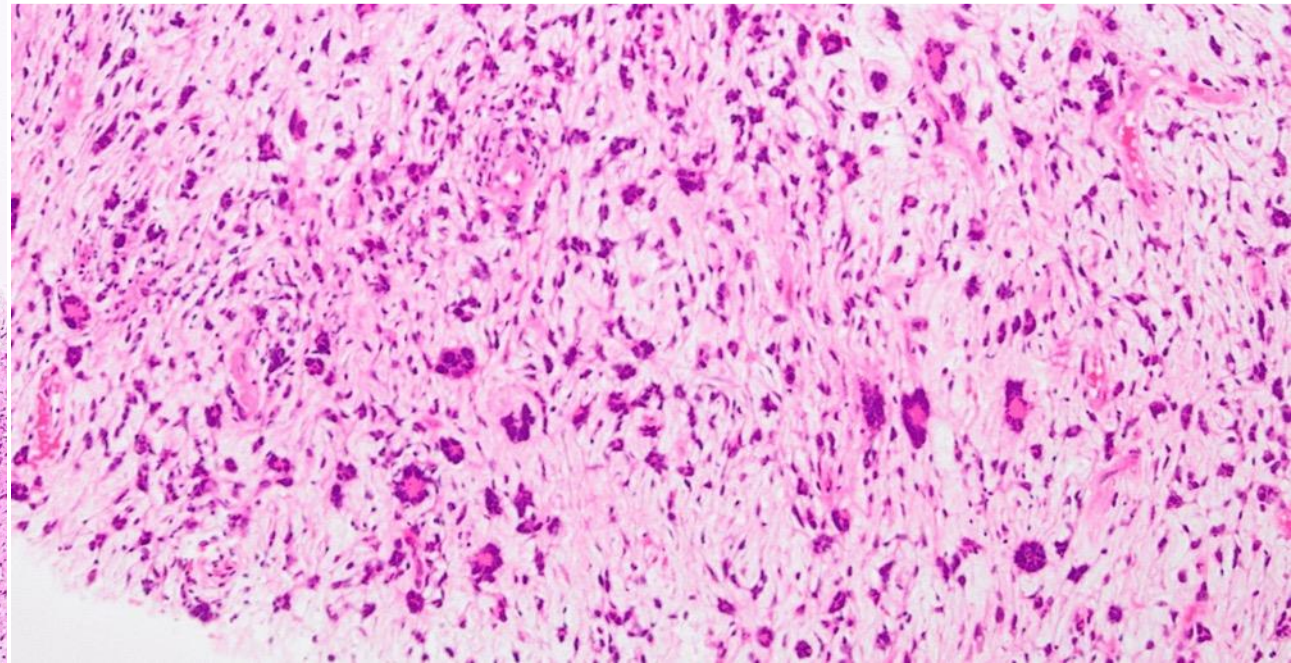

# 配布標本① 針生検検体

症例2

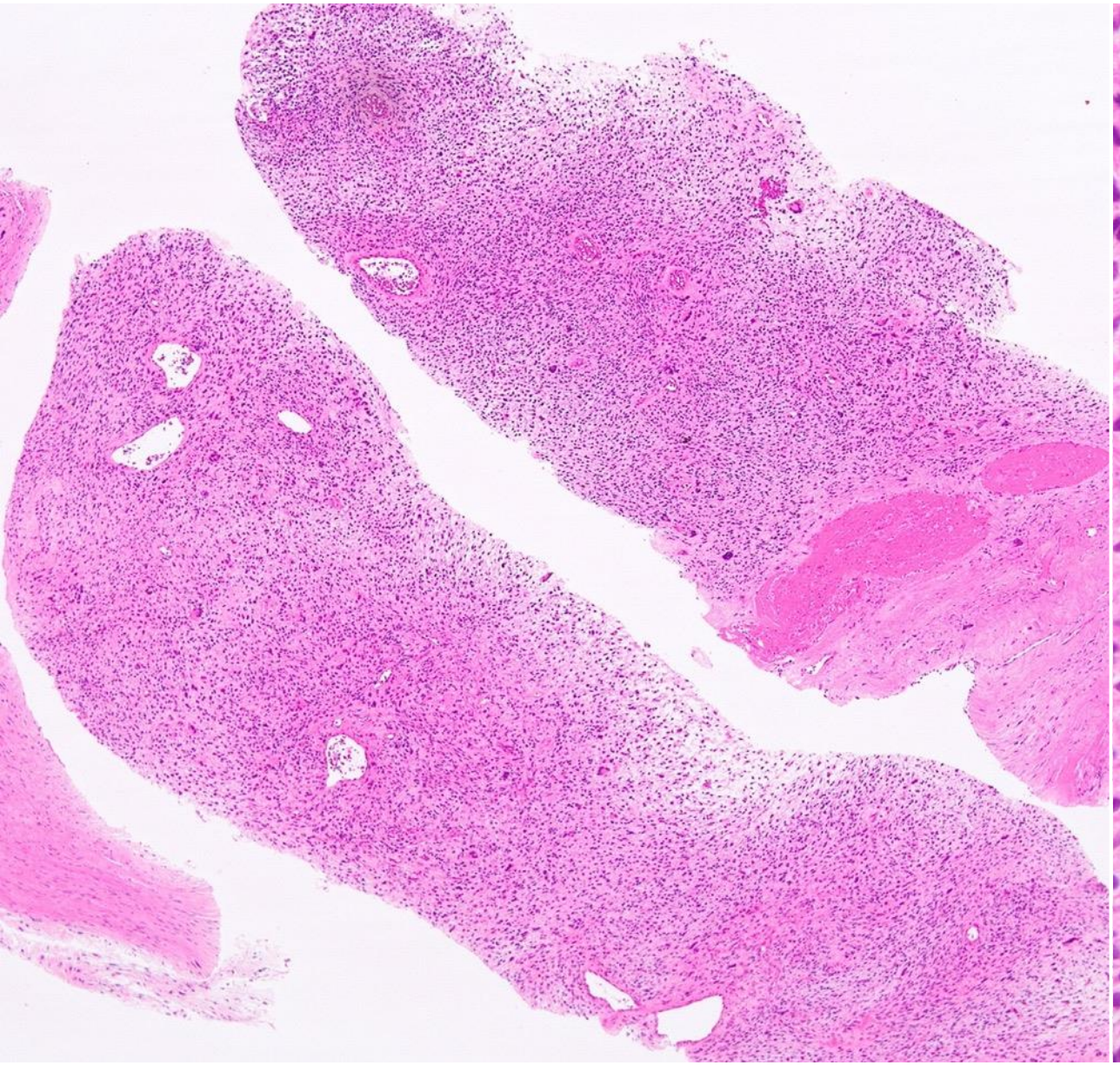

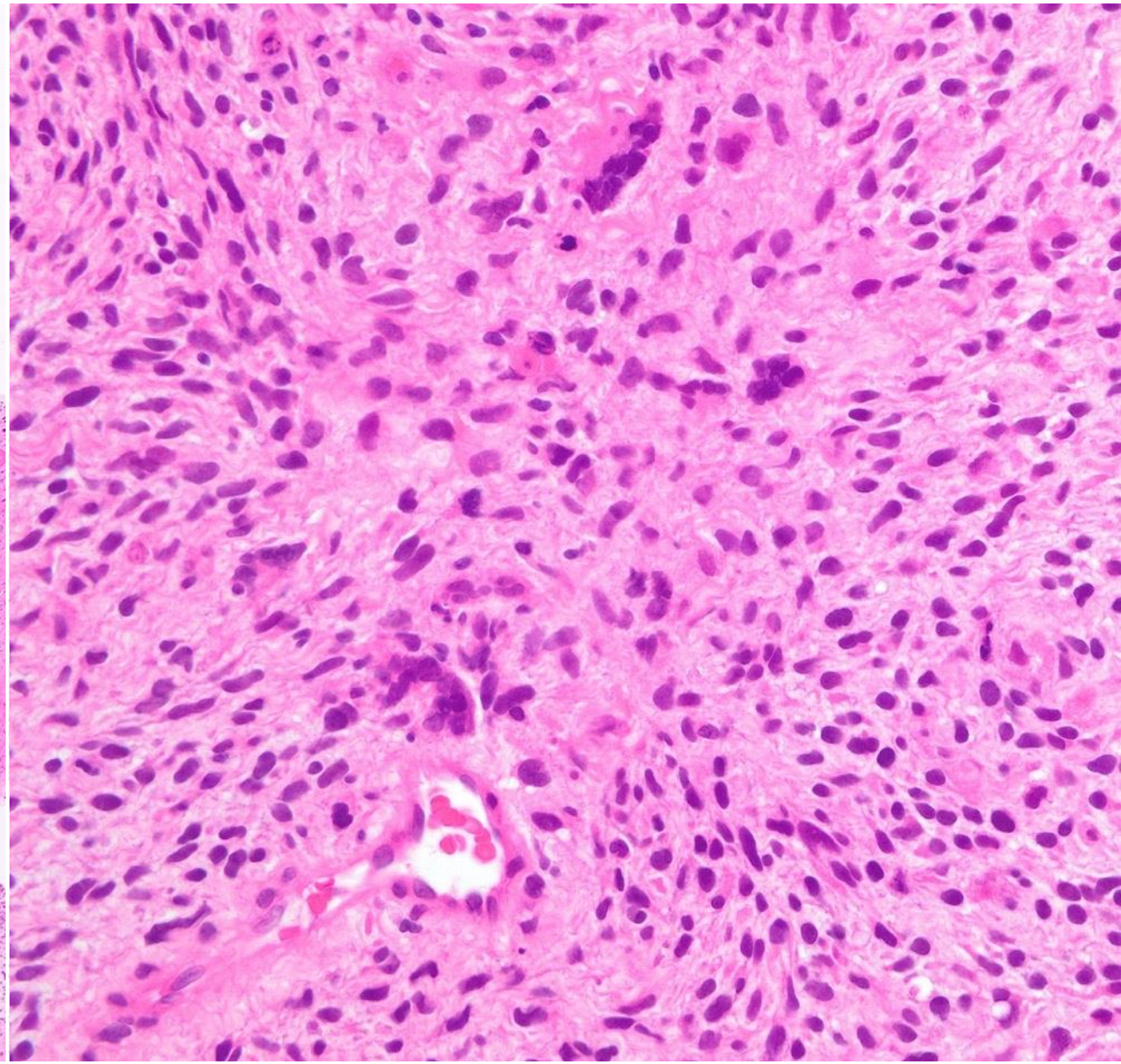

# 未配布標本 切開生検検体

症例2

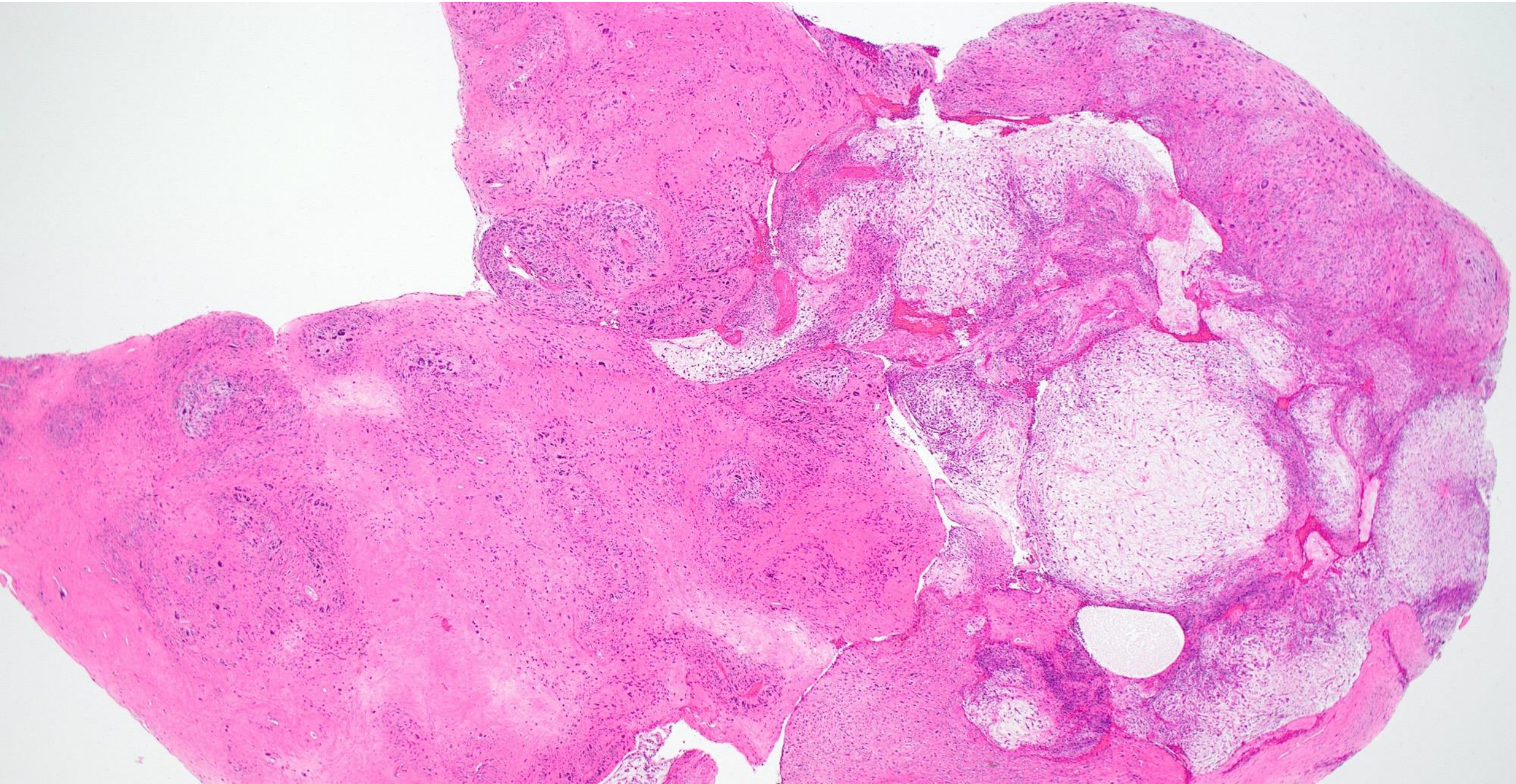

# 未配布標本 切開生検検体

症例2

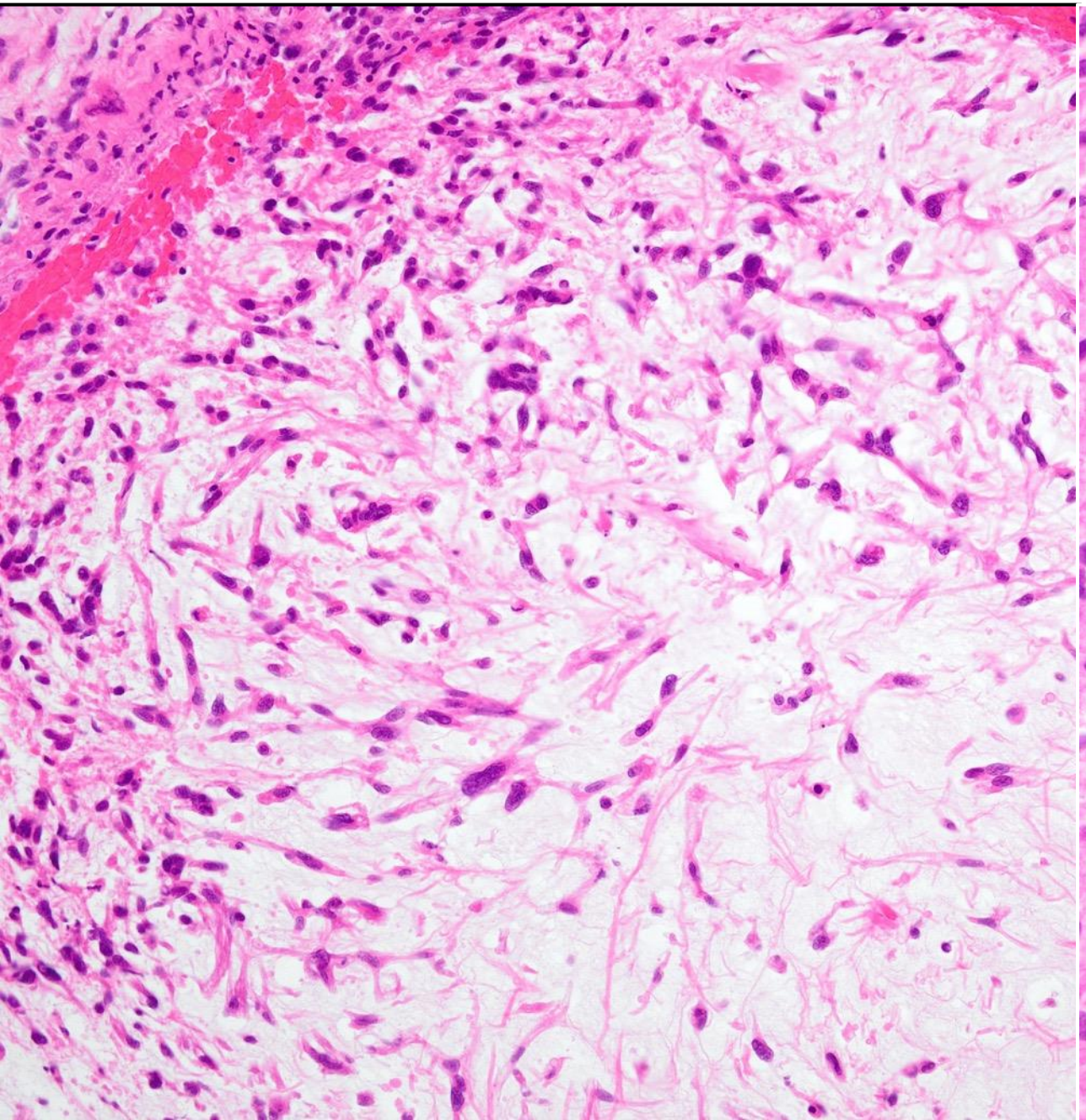

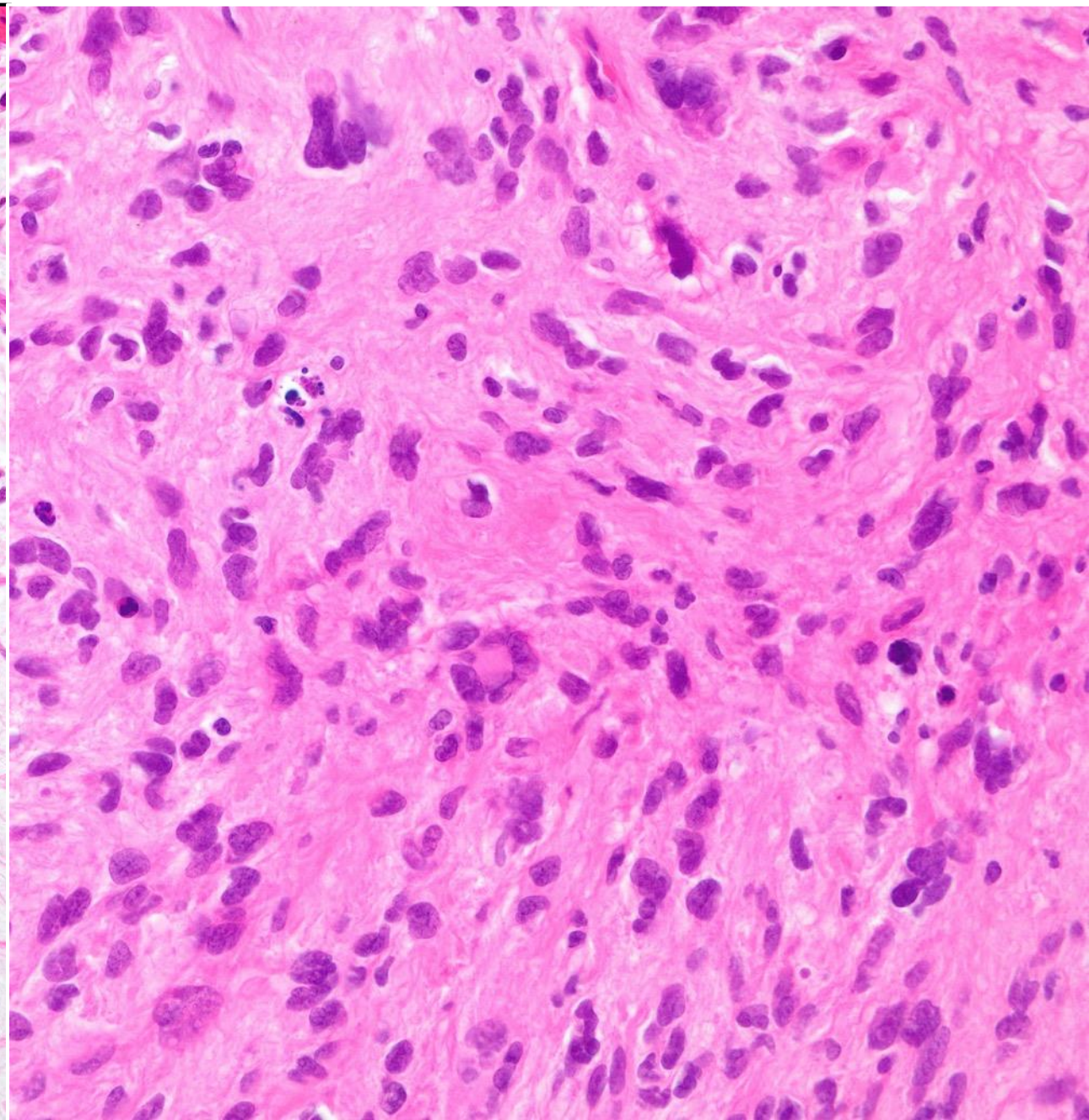

症例2

切除検体 (9.5×9.0×4.7 cm)

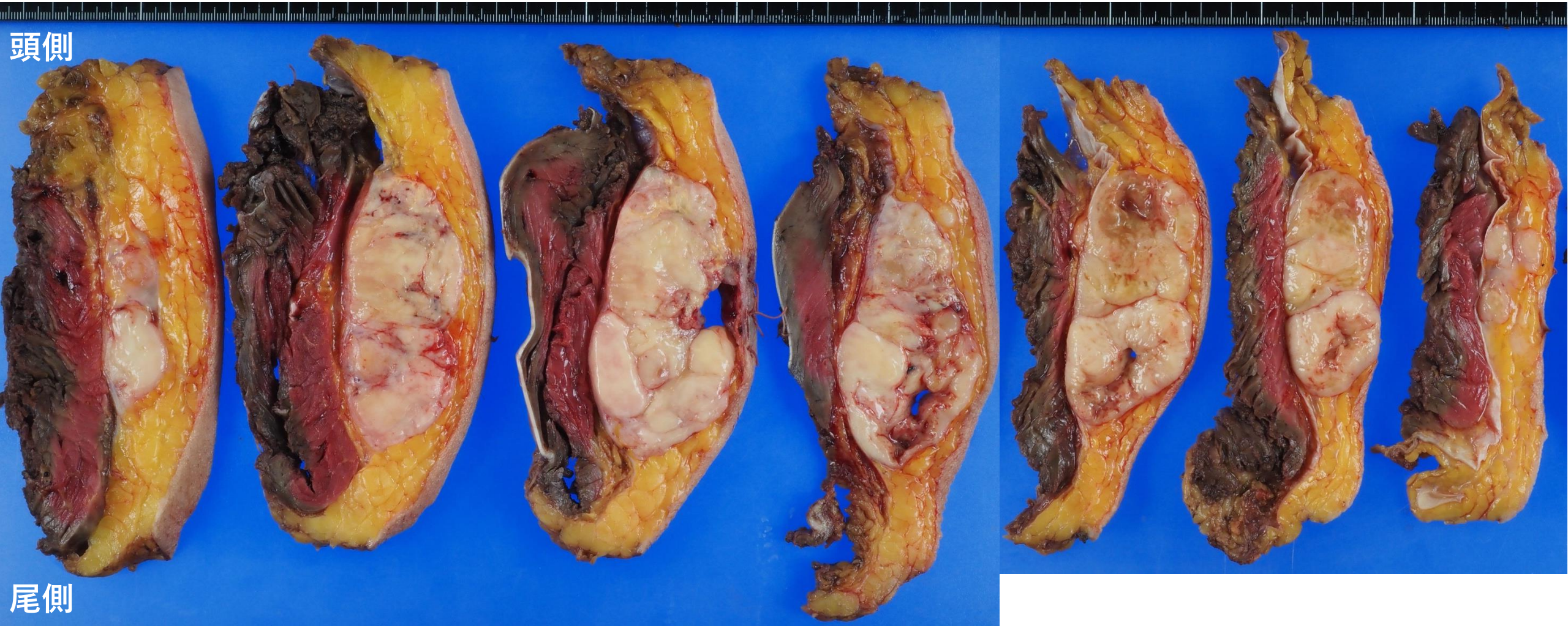

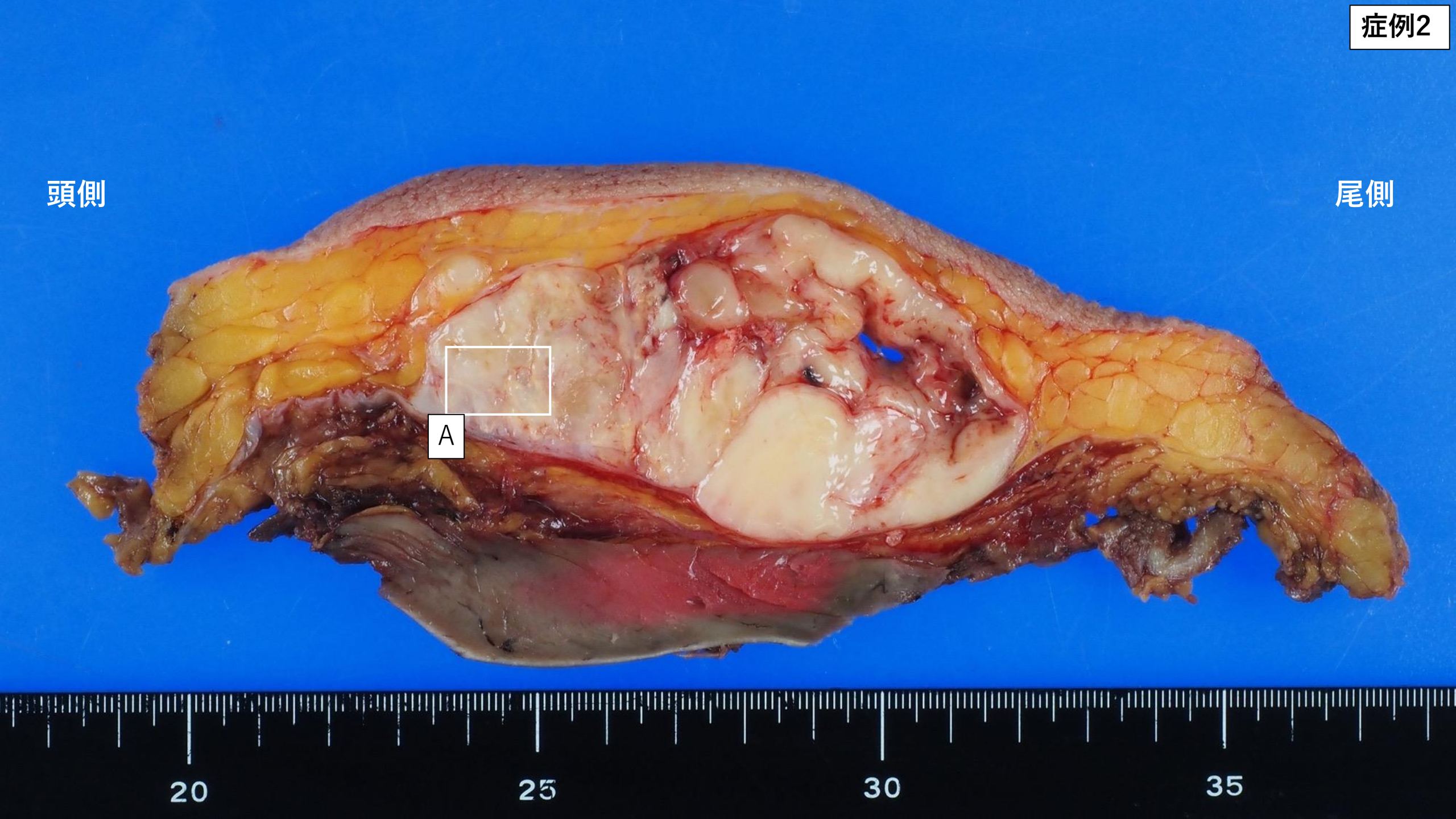
症例2
頭側
尾側
A
20
25
30
35

# 未配布標本(A) 切除検体

症例2

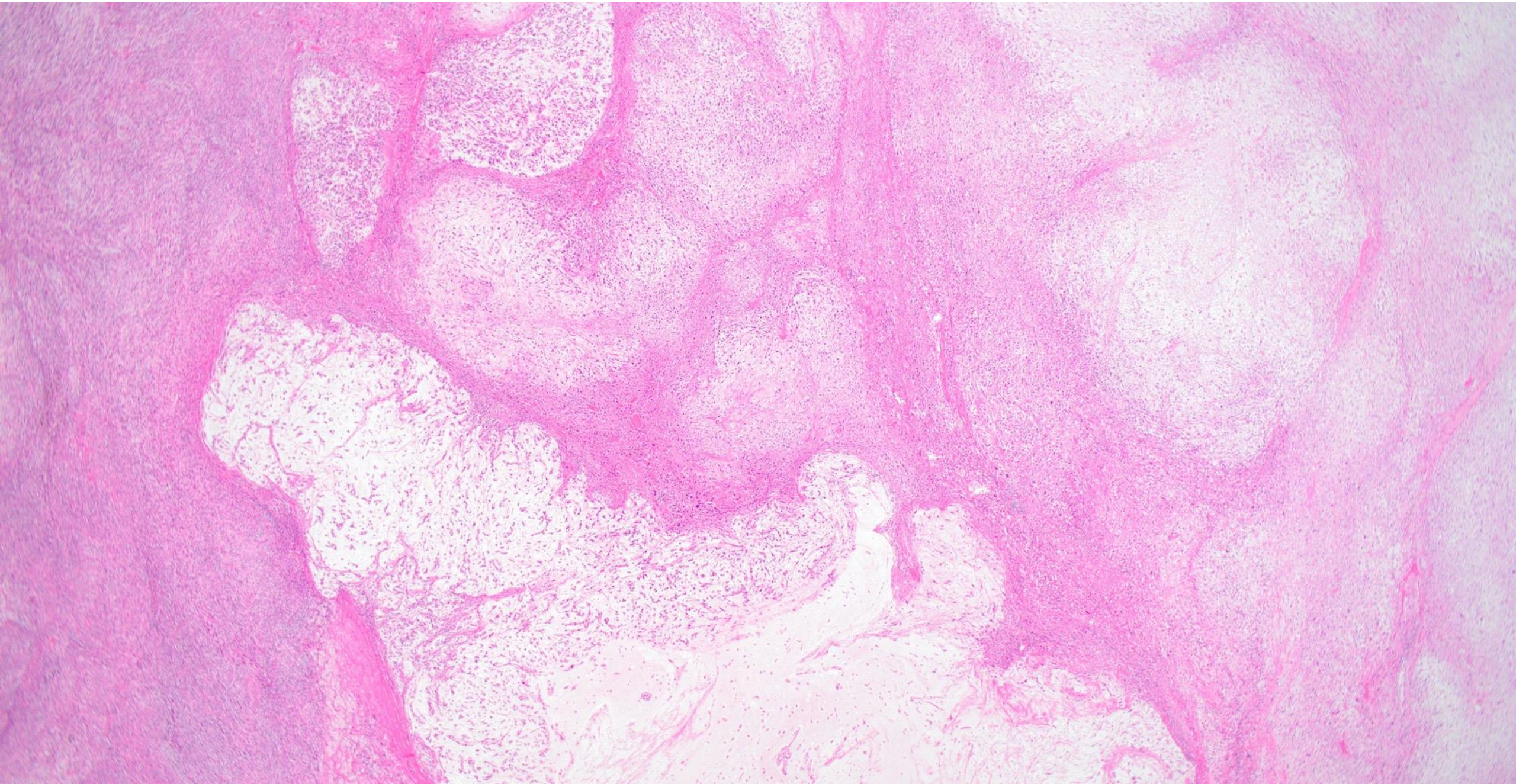

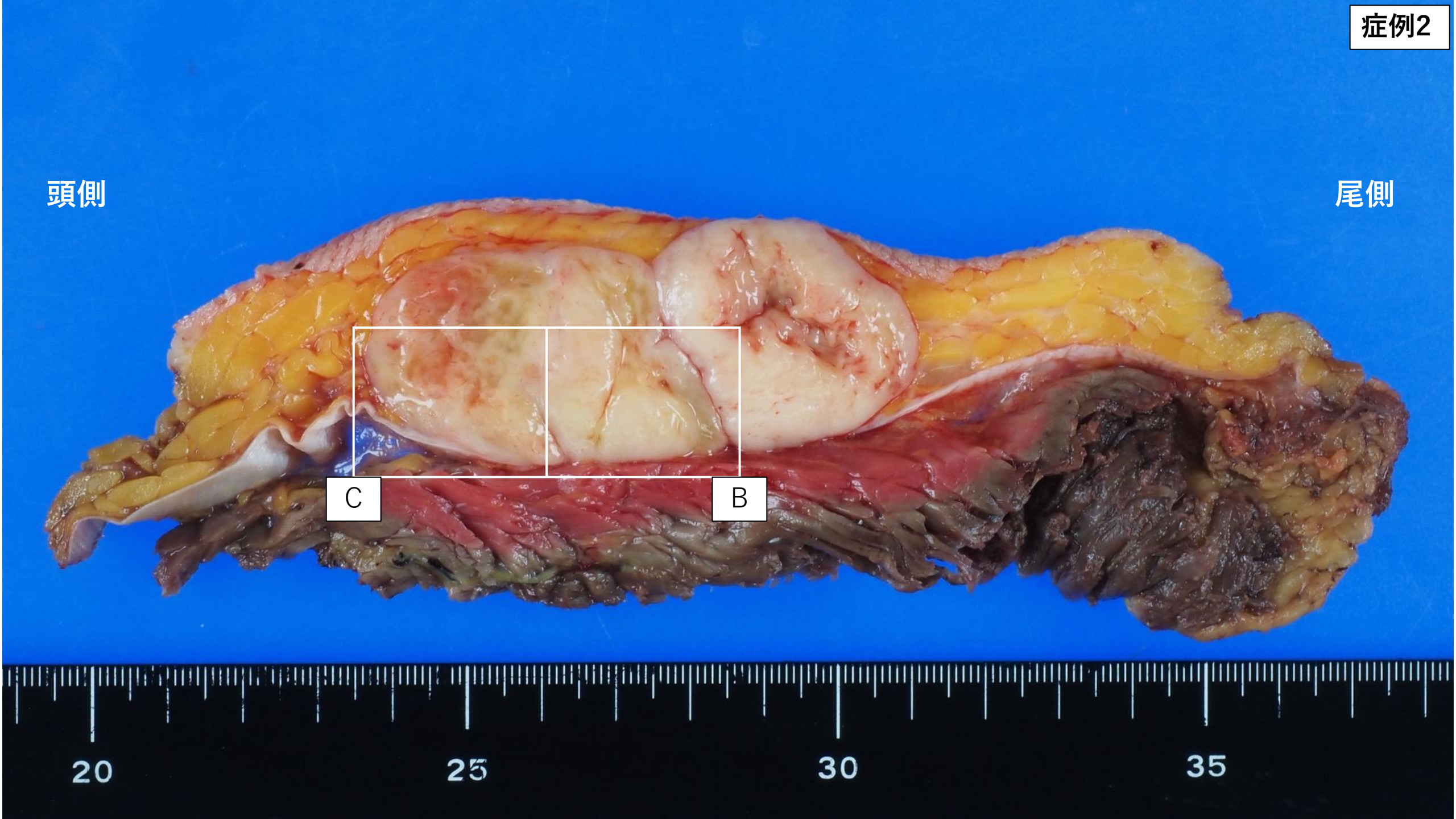
症例2
頭側
尾側
C
B
20
25
30
35

# 配布標本②(B) 切除検体

症例2

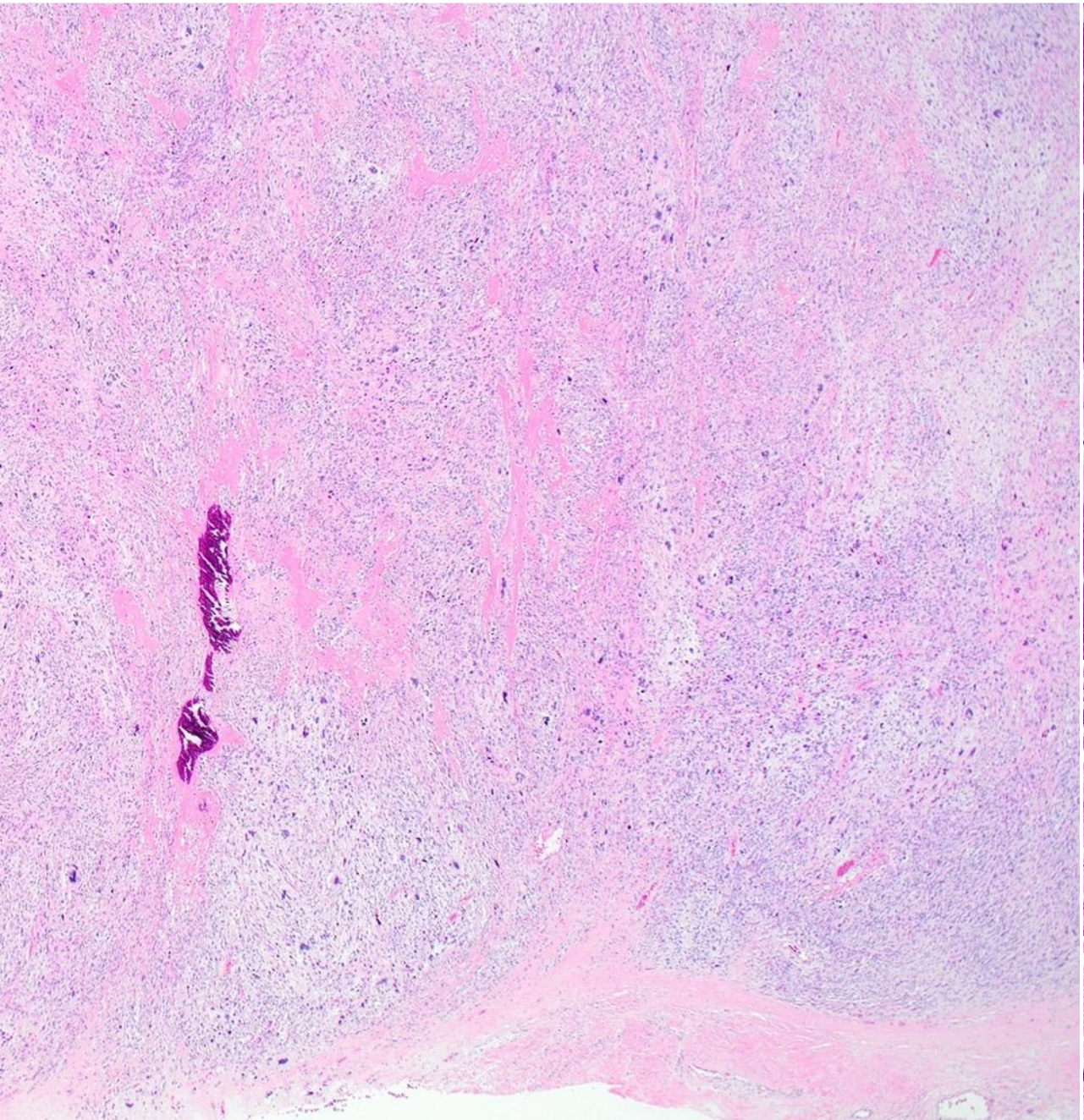

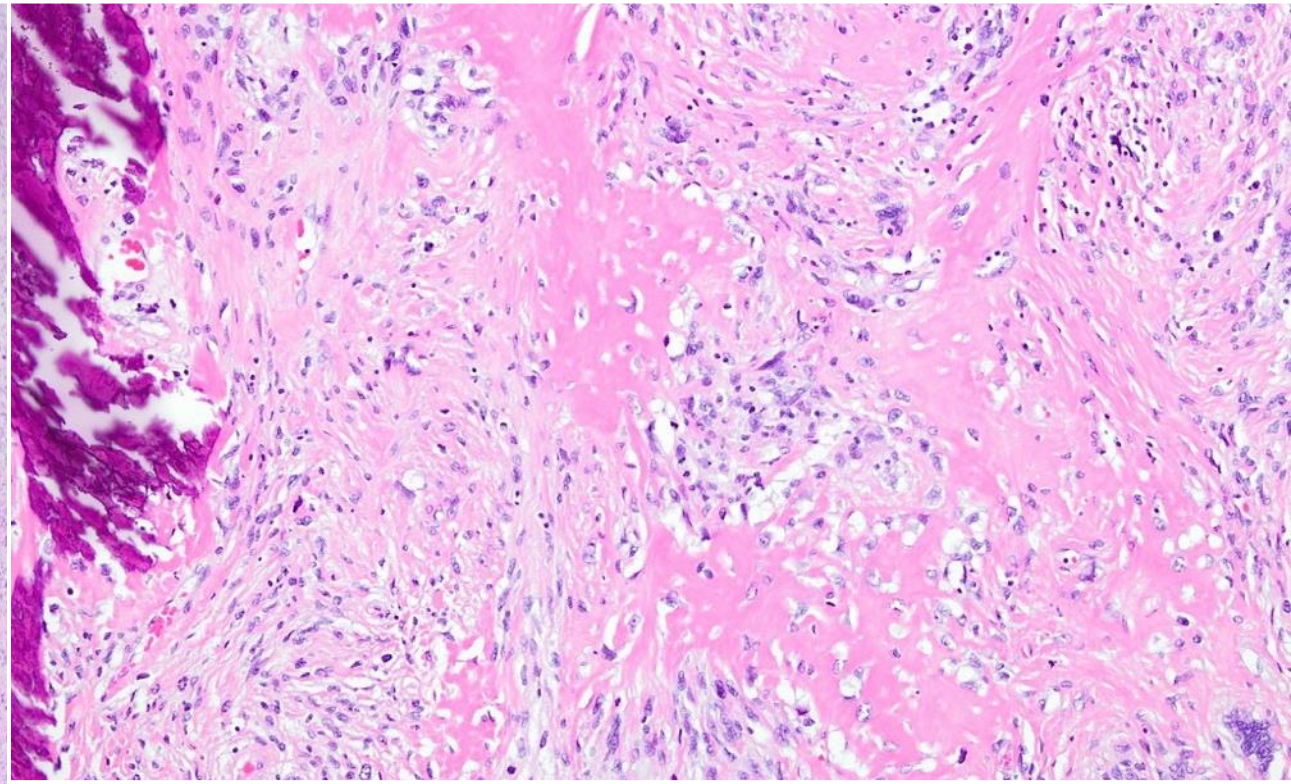

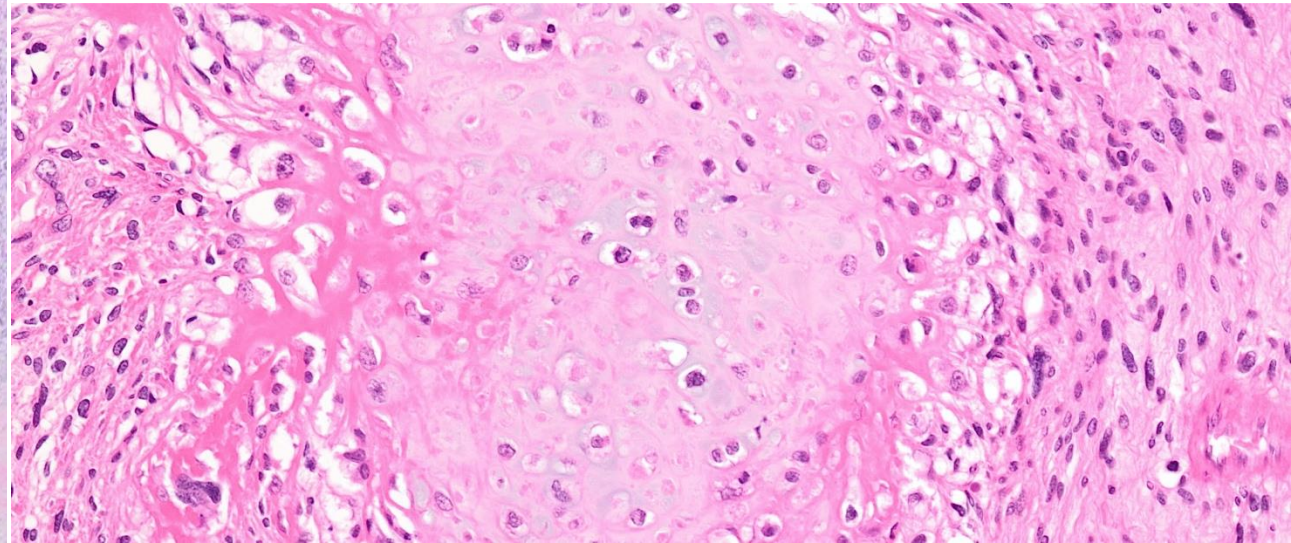

# 配布標本③(C) 切除検体

症例2

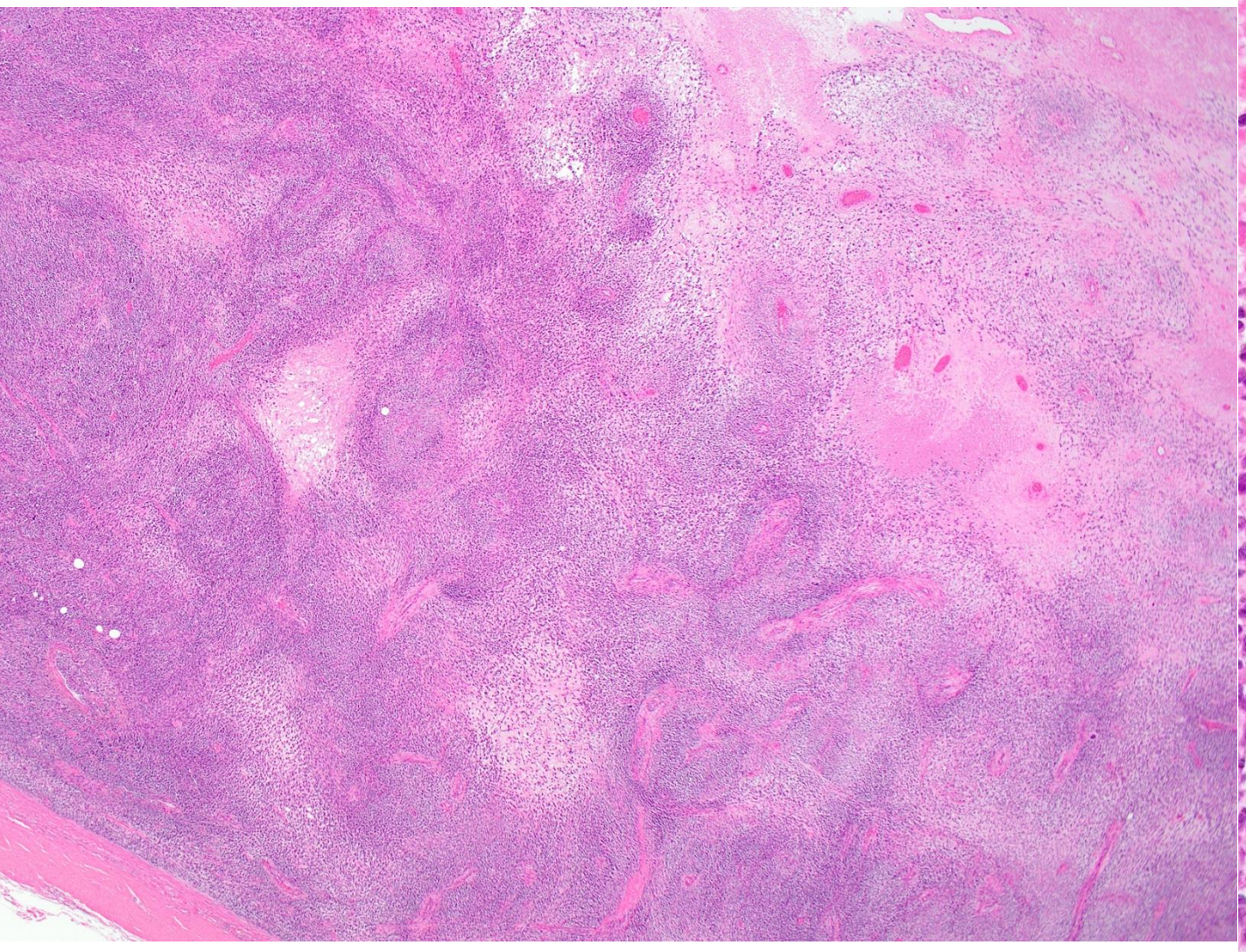

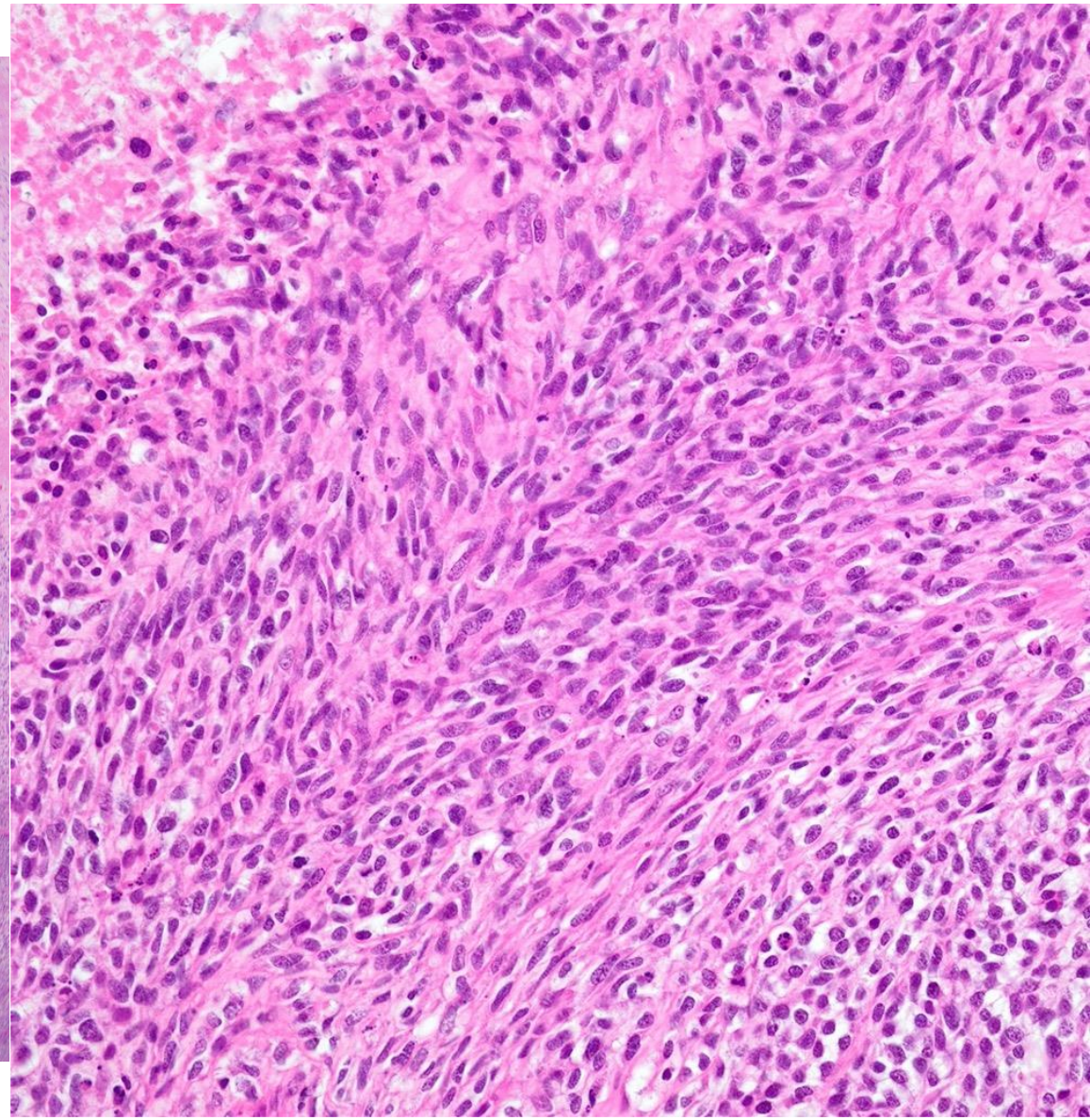

# 症例３

千葉県がんセンター
臨床病理部

症例3

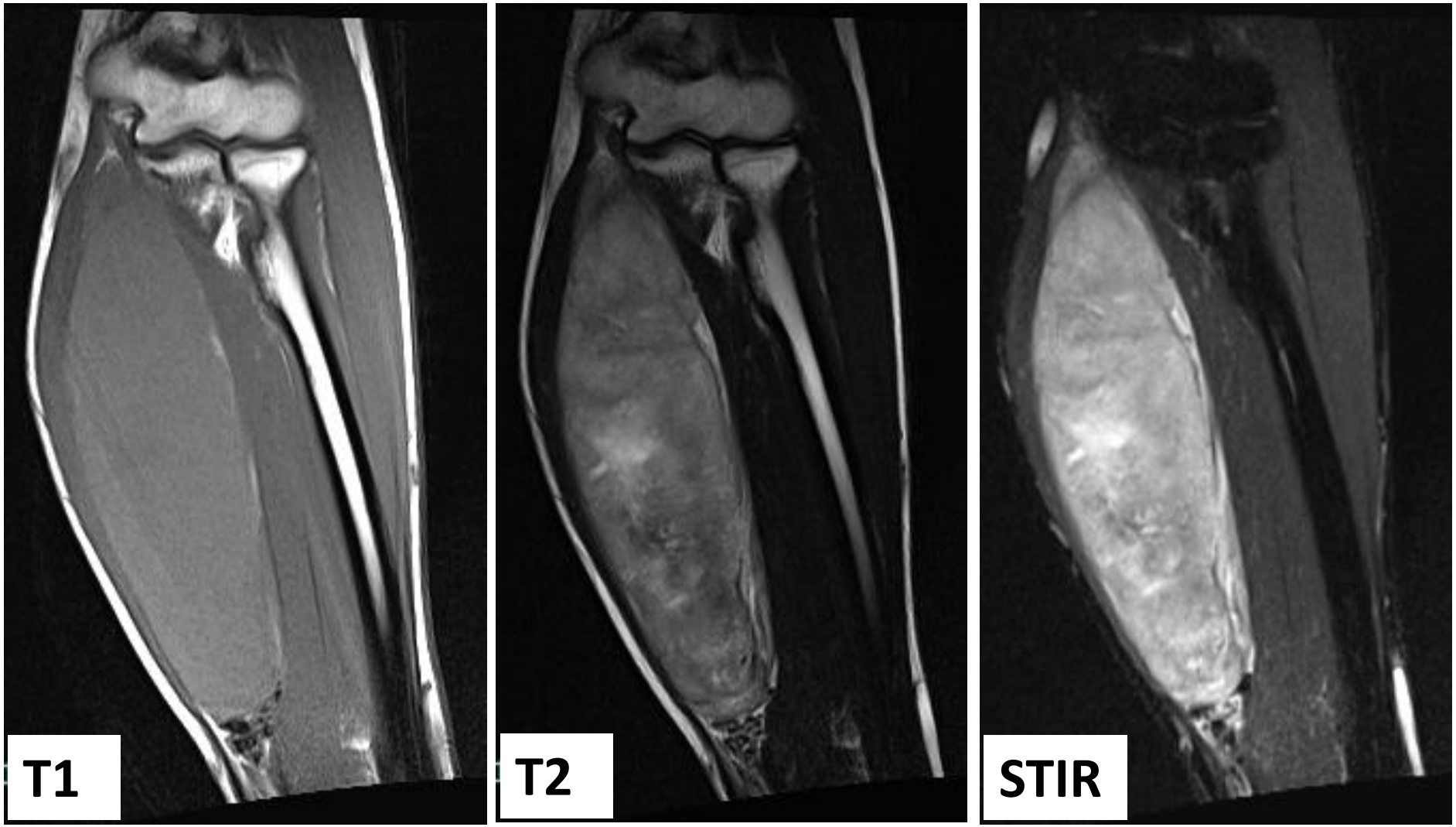

症例3

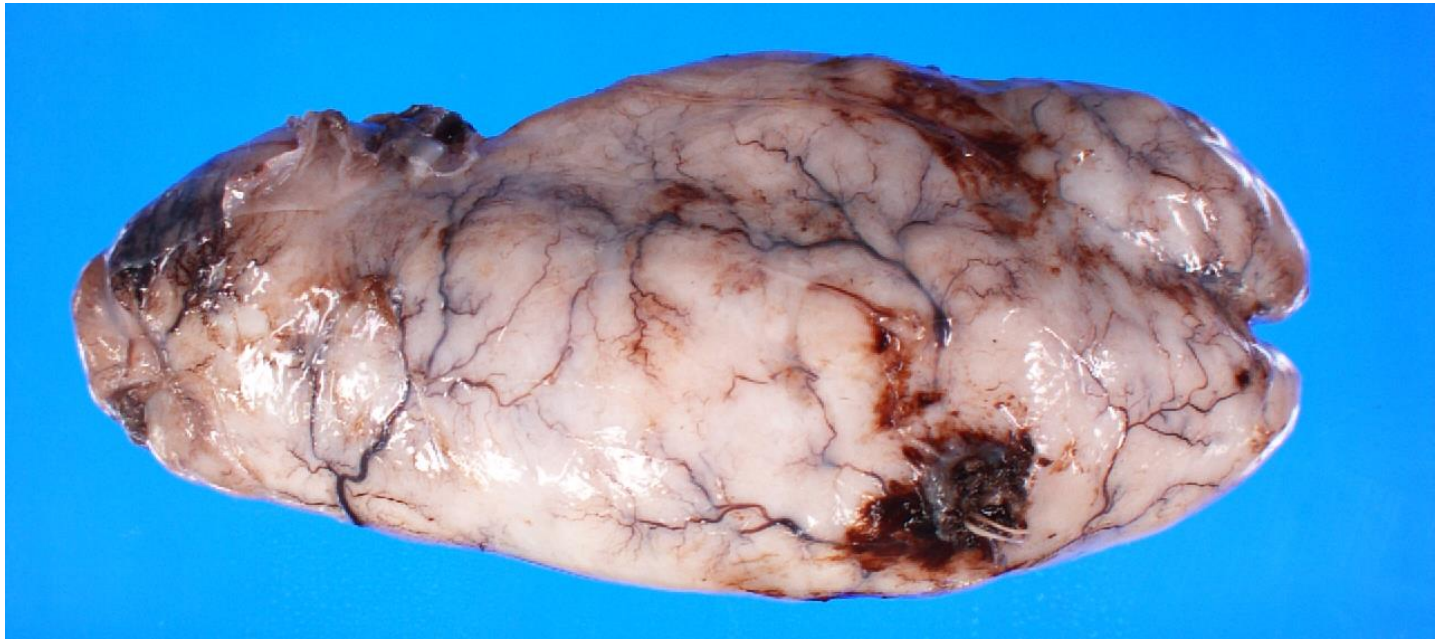

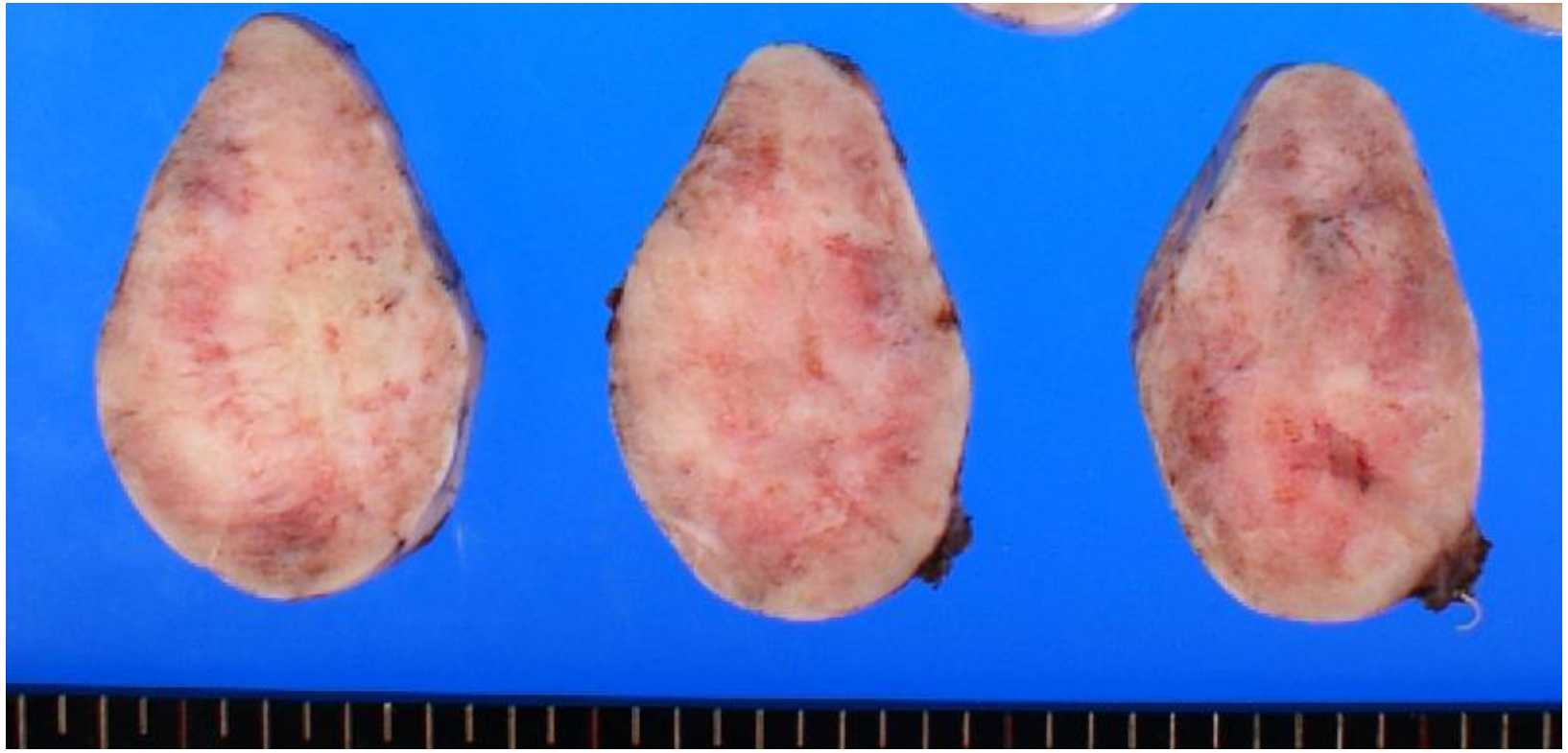

# 症例 4

埼玉県立がんセンター
病理診断科

症例4

# MRI T2WI [前医]
## (症状自覚から3ヶ月)

症例4

## 単純CT［前々医］
（症状自覚から2ヶ月）

## 造影CT［前医］
（症状自覚から3ヶ月）

10cm

## 造影CT［当院術前］
（症状自覚から4ヶ月）

症例4

# 摘出検体

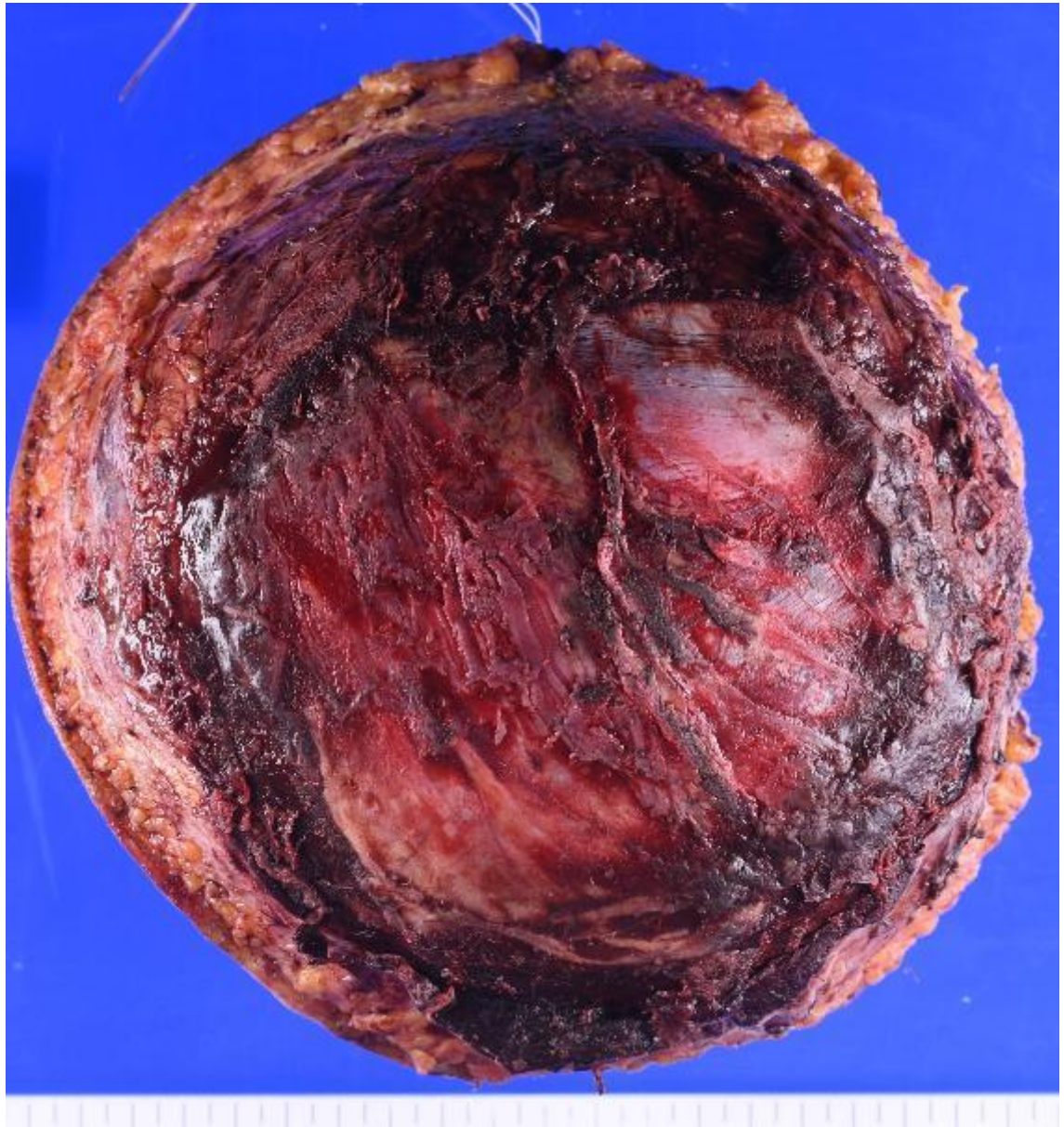

症例4

# 腫瘍割面(水平断)

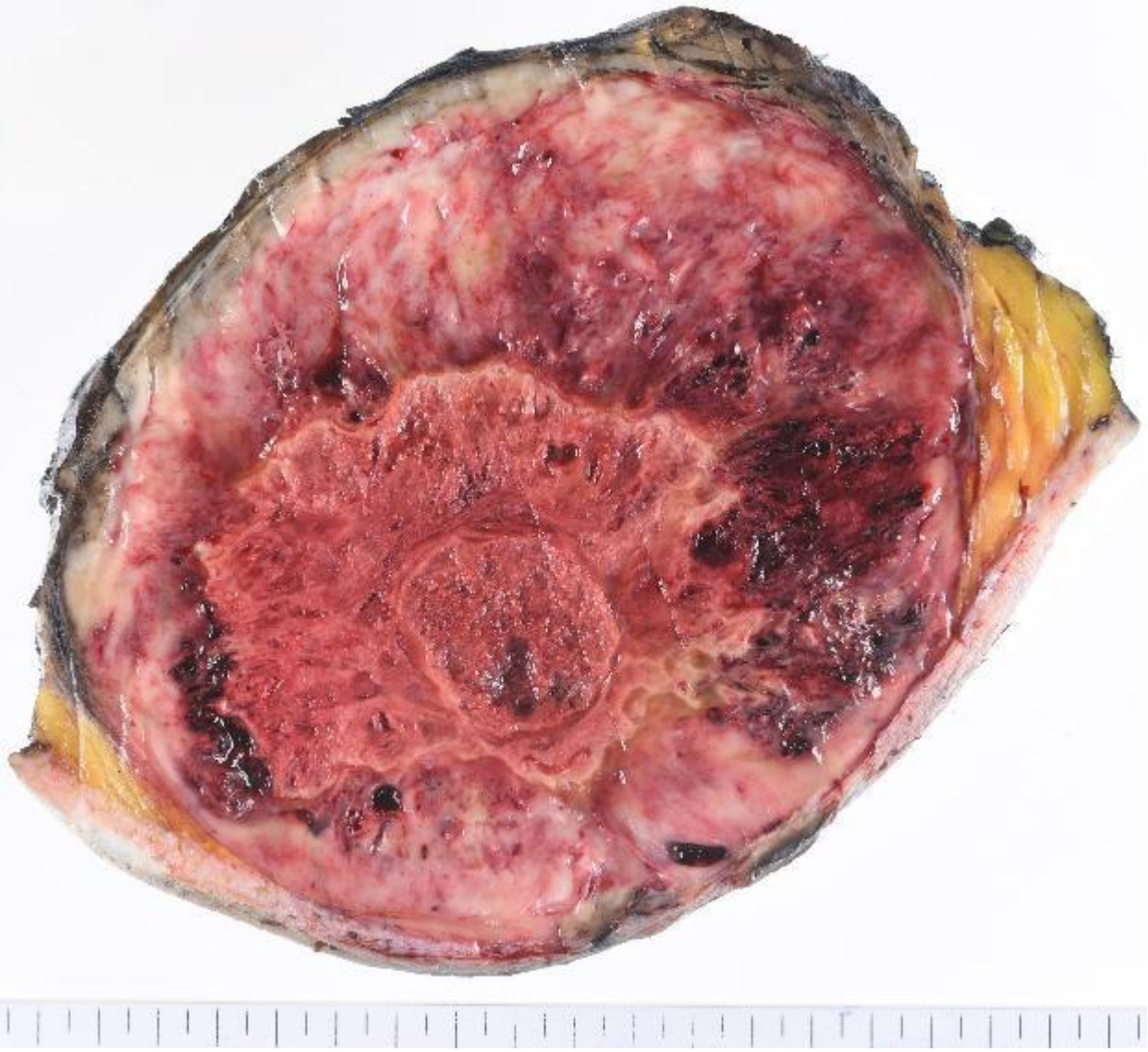

# MRI T2WI [前医]

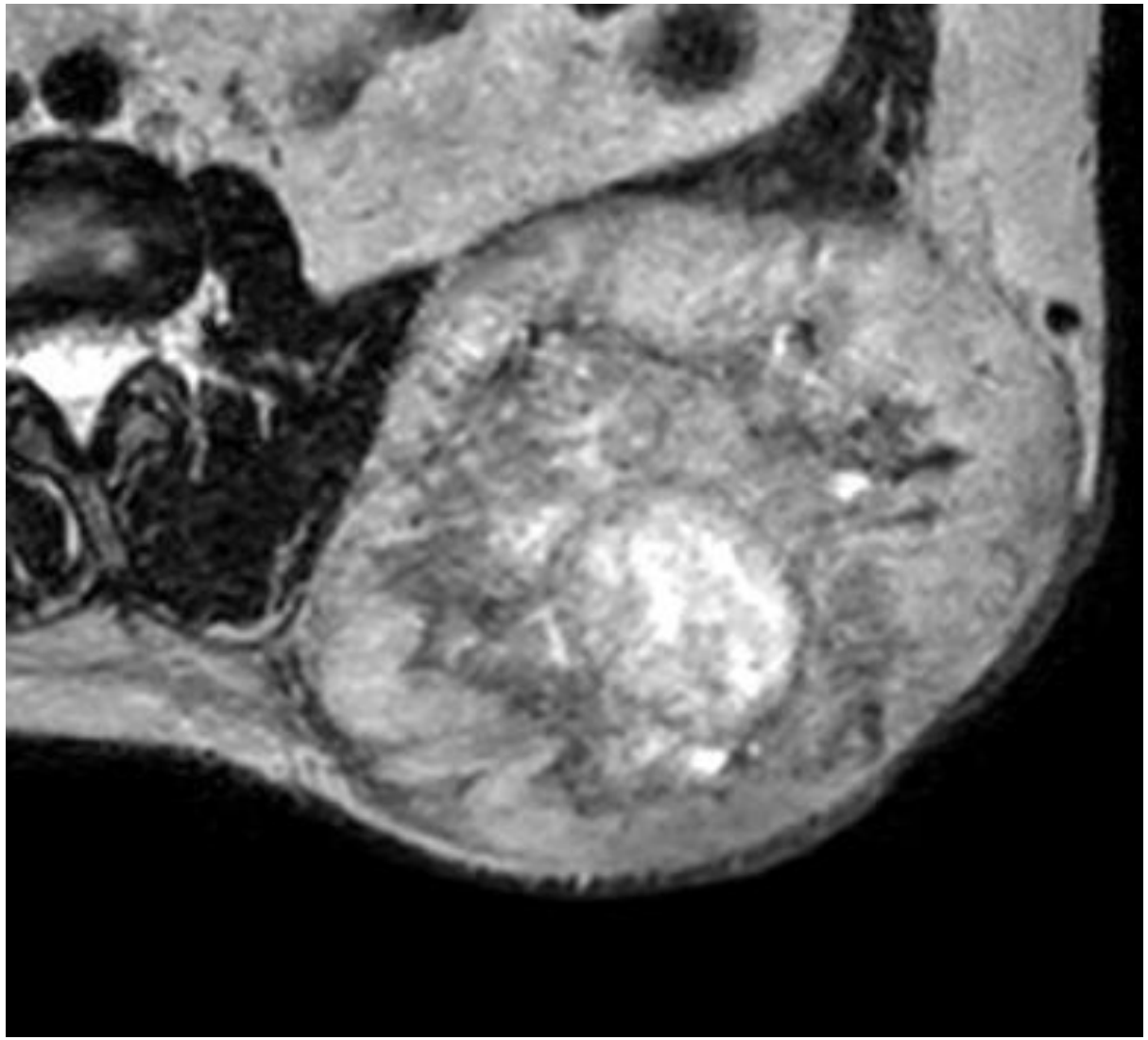

# 症例 5

都立駒込病院 病理診断科
聖マリアンナ医科大学 病理学講座

他院CT　X-21年　踵部初発病変

**症例5**

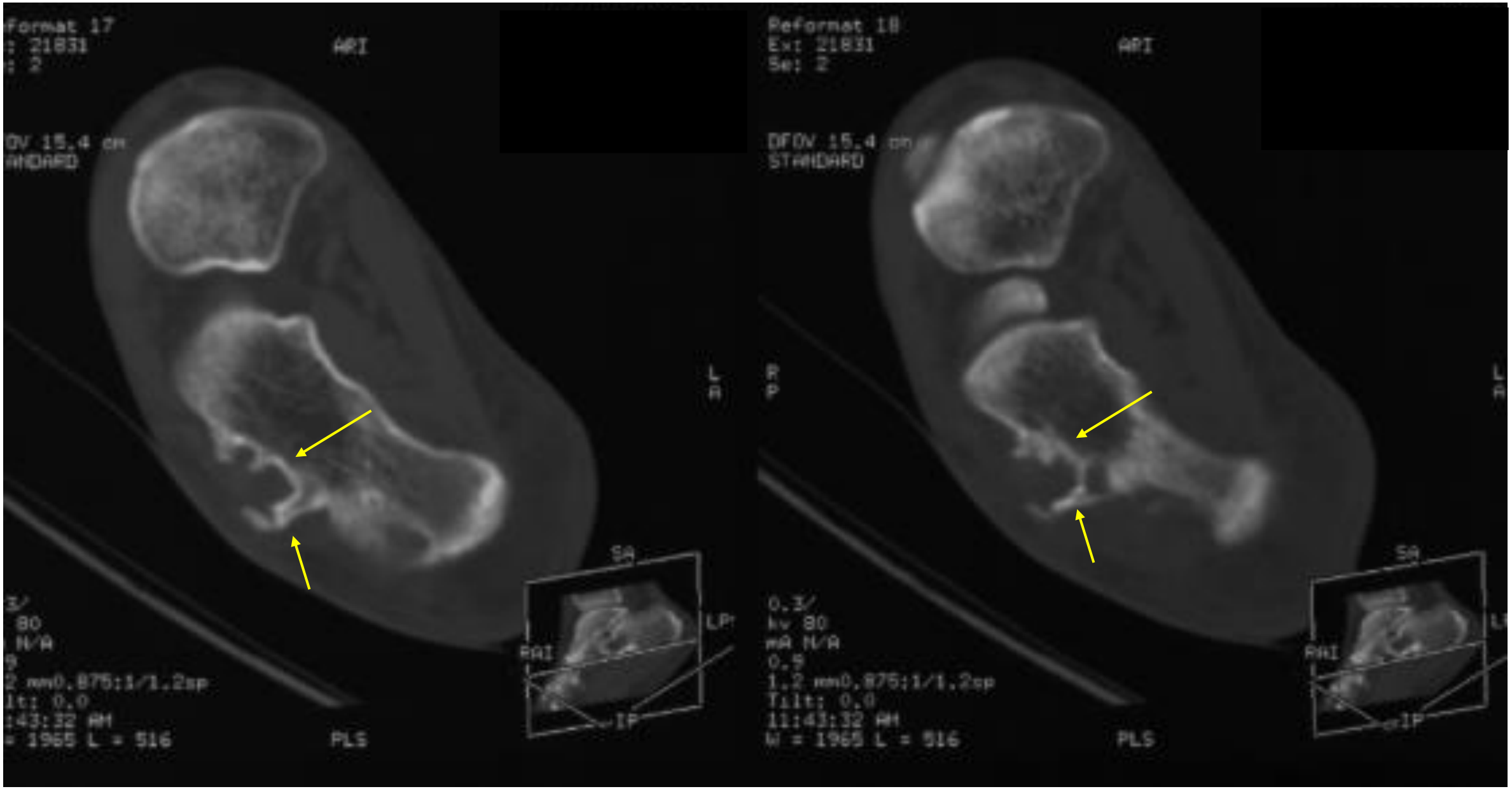

症例5

当院CT　X年　右下腿部再発病変

# 症例 6

九州大学病院
病理部/病理診断科

# CT検査(10ヶ月前)

症例6

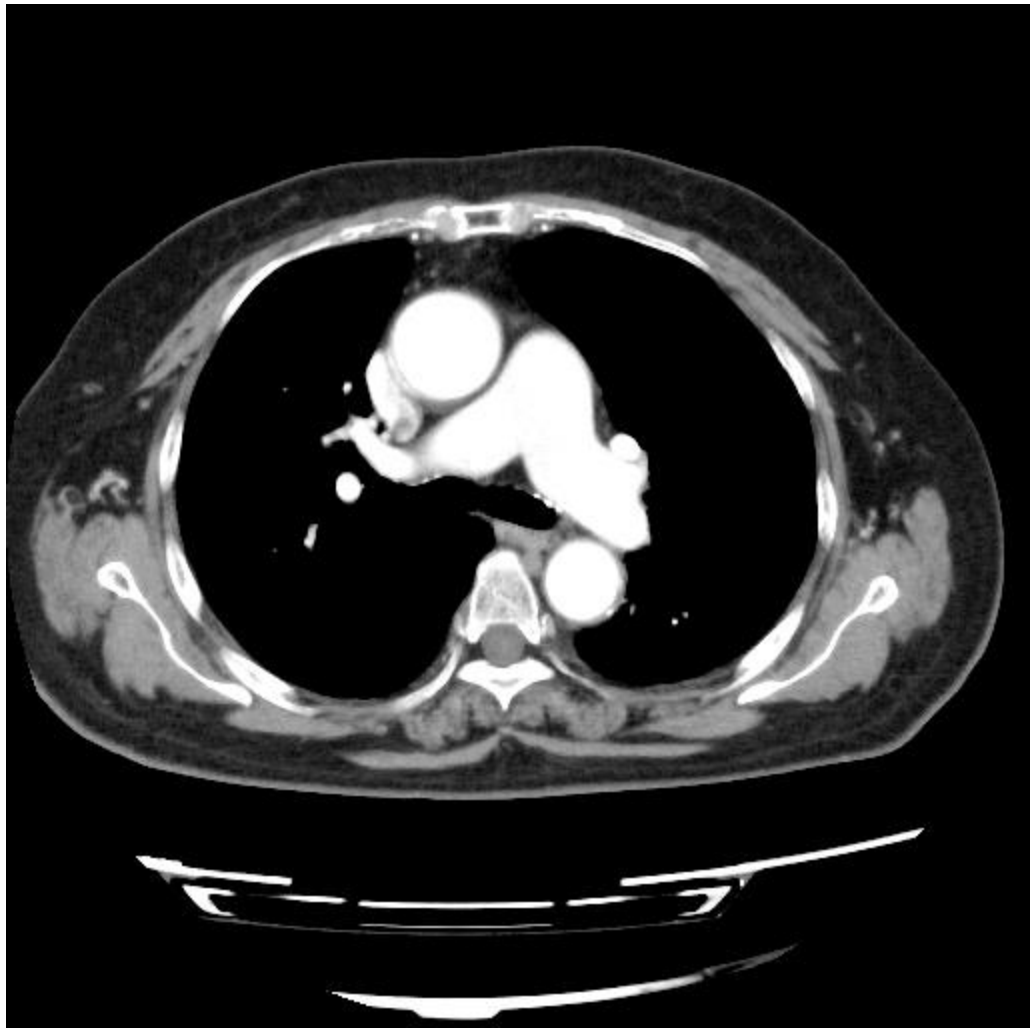

**血栓、腫瘍等なし**

# CT検査(4ヶ月前)

症例6

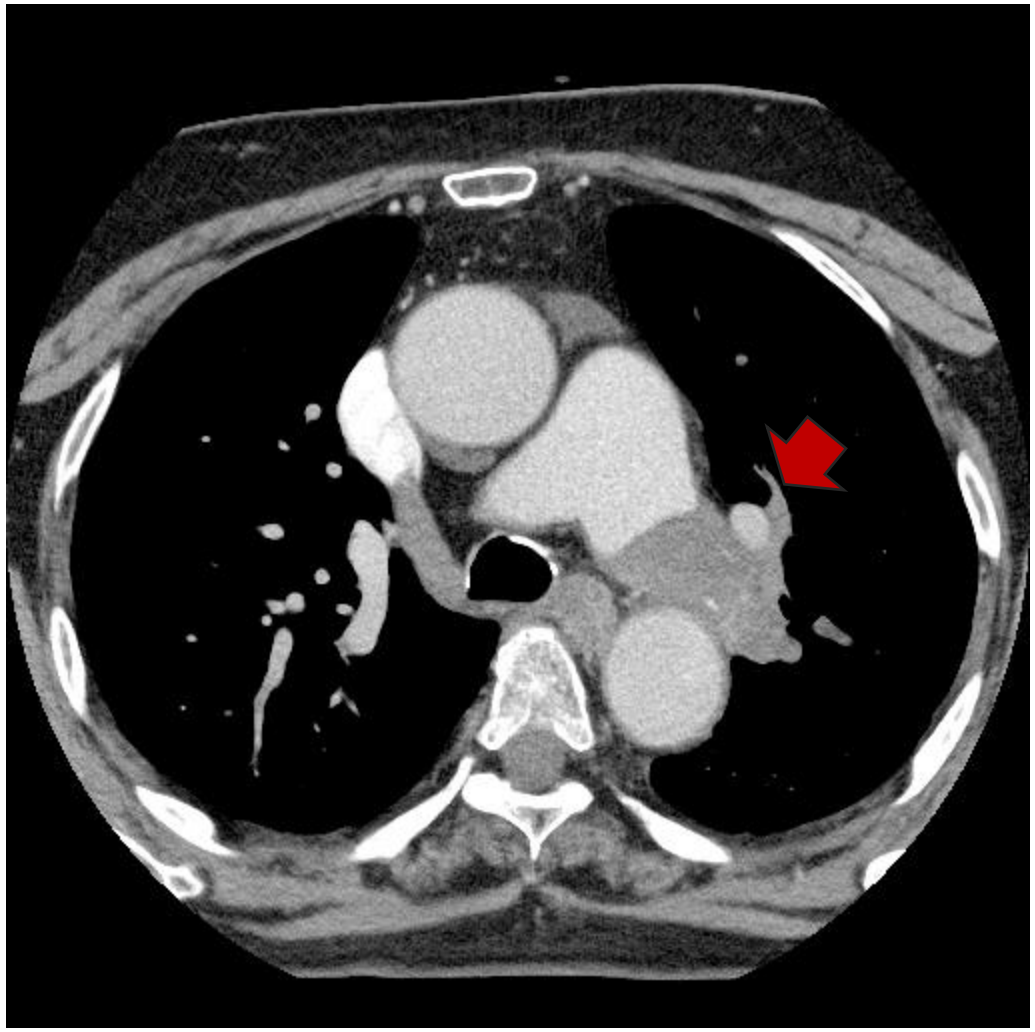

左肺近位部に血栓様所見あり

# CT検査(1ヶ月前)

症例6

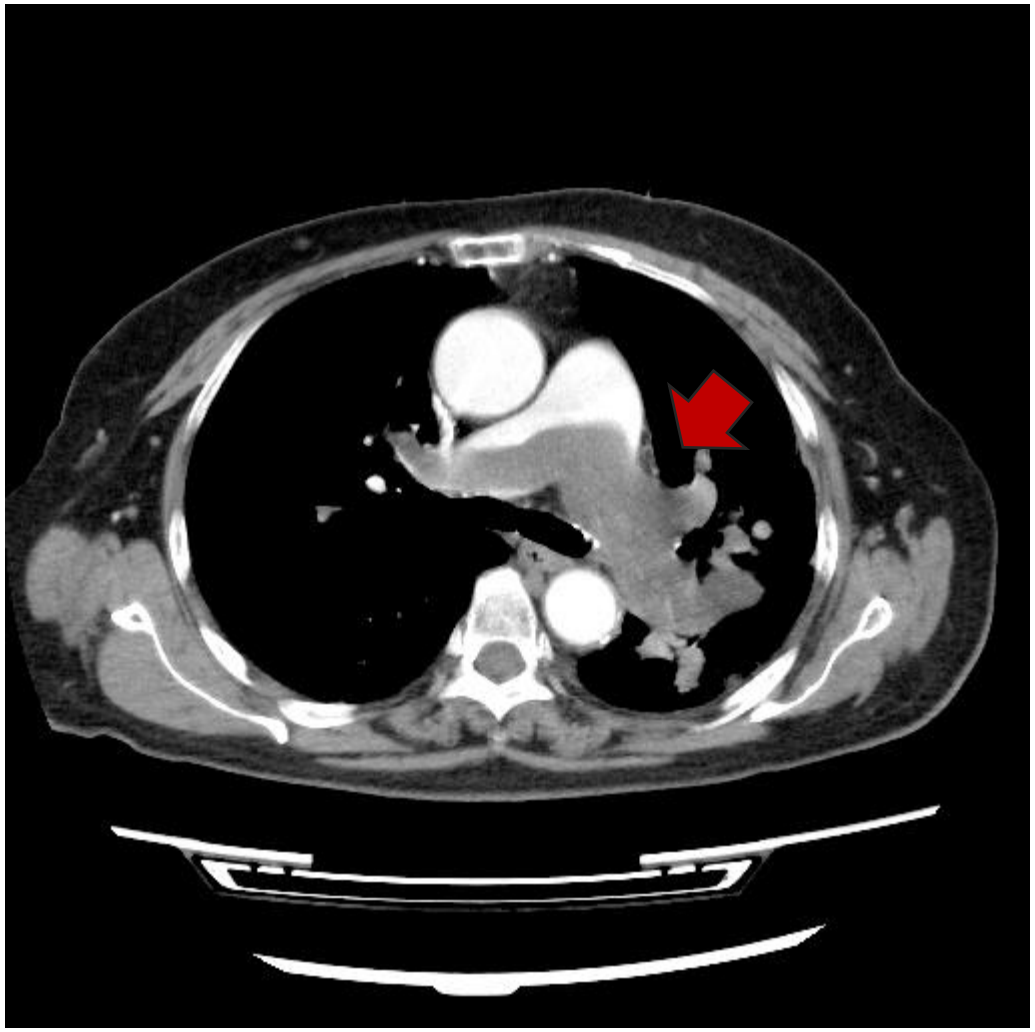

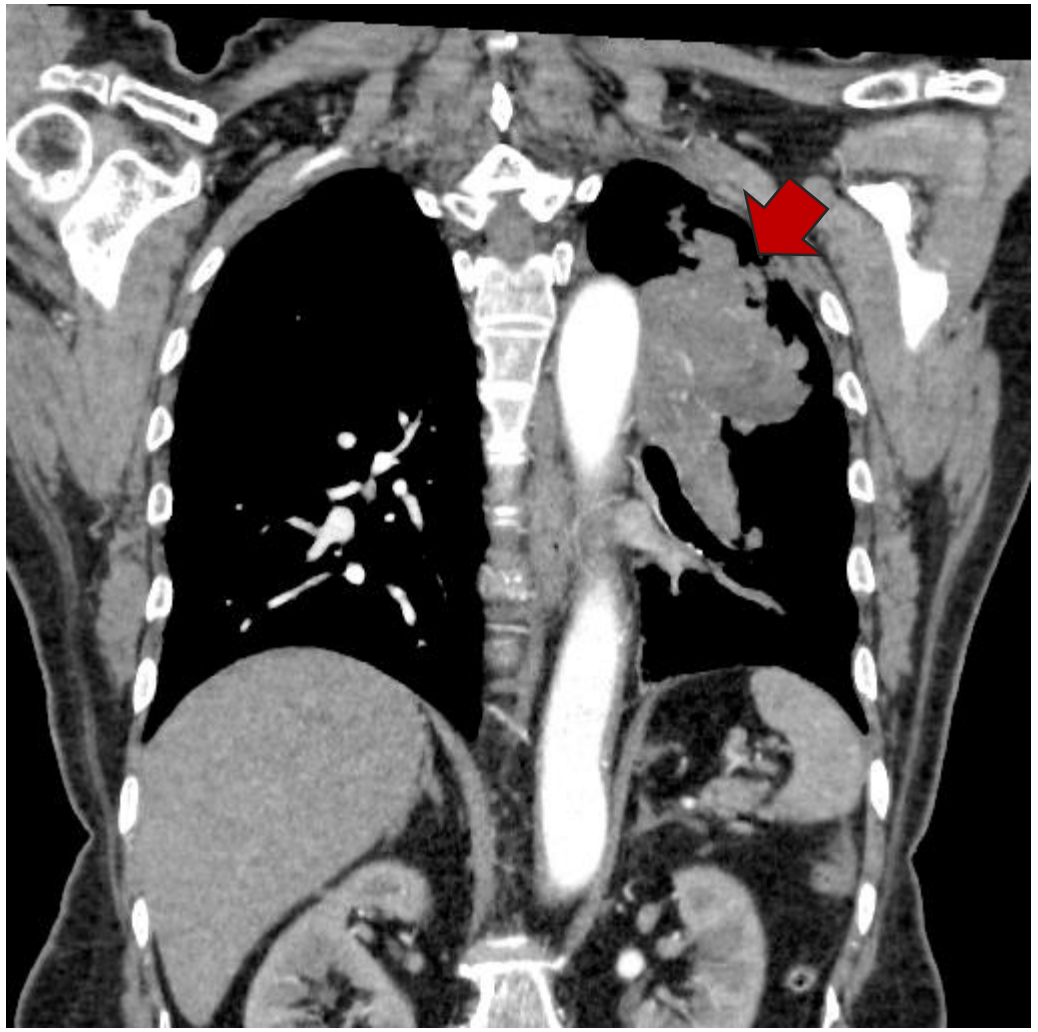

**左肺動脈本幹～区域枝内腔に病変が充満**

# CT検査(1ヶ月前)

症例6

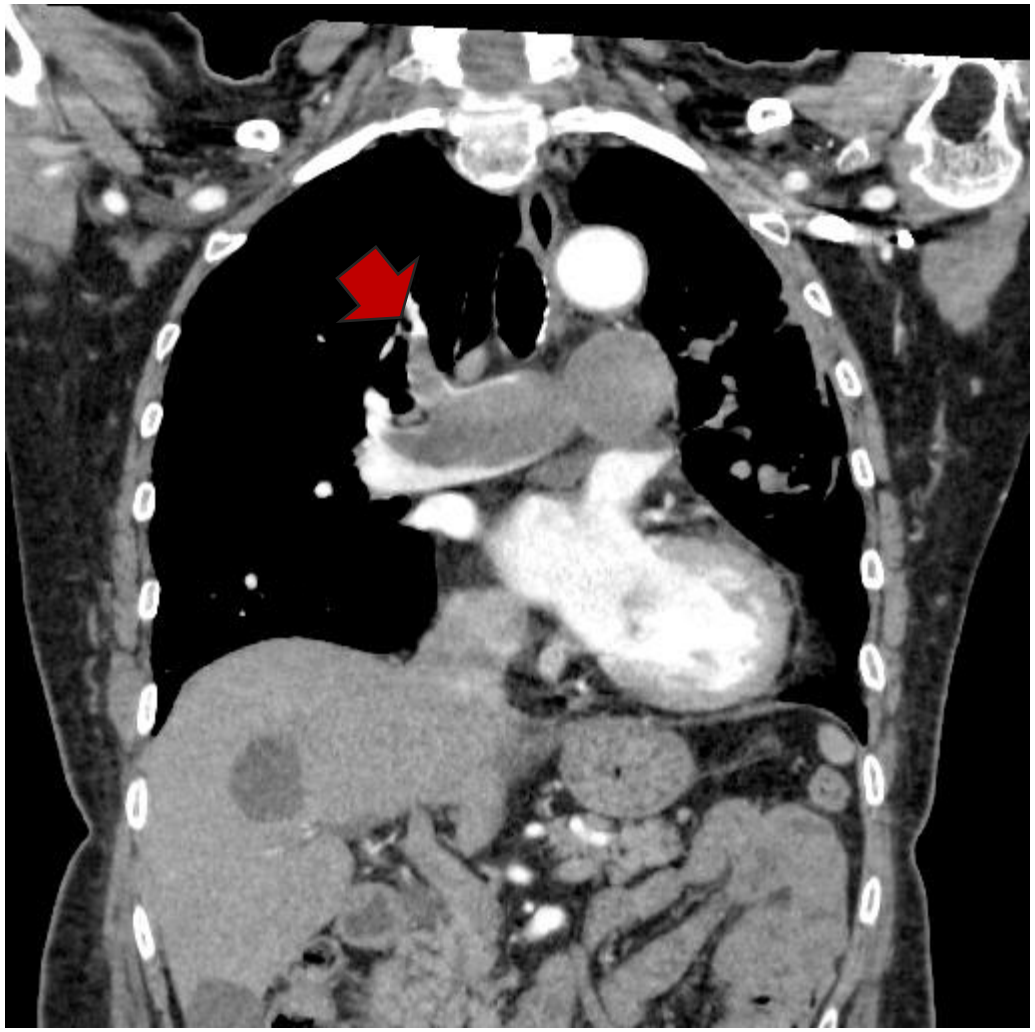

**右肺動脈本幹～上葉区域枝内腔に進展**